SSS Enfeksiyonlarının Radyolojik Tanısı

Dr. Ömer Kitiş
Ege Üniversitesi Tıp Fakültesi
Radyoloji Anabilim Dalı
Nöroradyoji

- Nöroradyoloji de;doku kontrast mekanizmaları
  - T1/T2/PD; T1-T2 relaksasyon zamanları
  - GRE
  - TOF, PC
  - MT; MT ratio
  - MR Spektroskopi
  - Perfüzyon MRG; CBV, CBF, MTT
  - fMRG; BOLD
  - Difüzyon MRG; ADC
  - DTI; FA

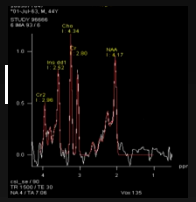

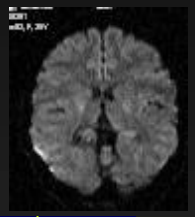

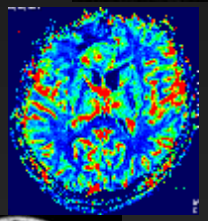



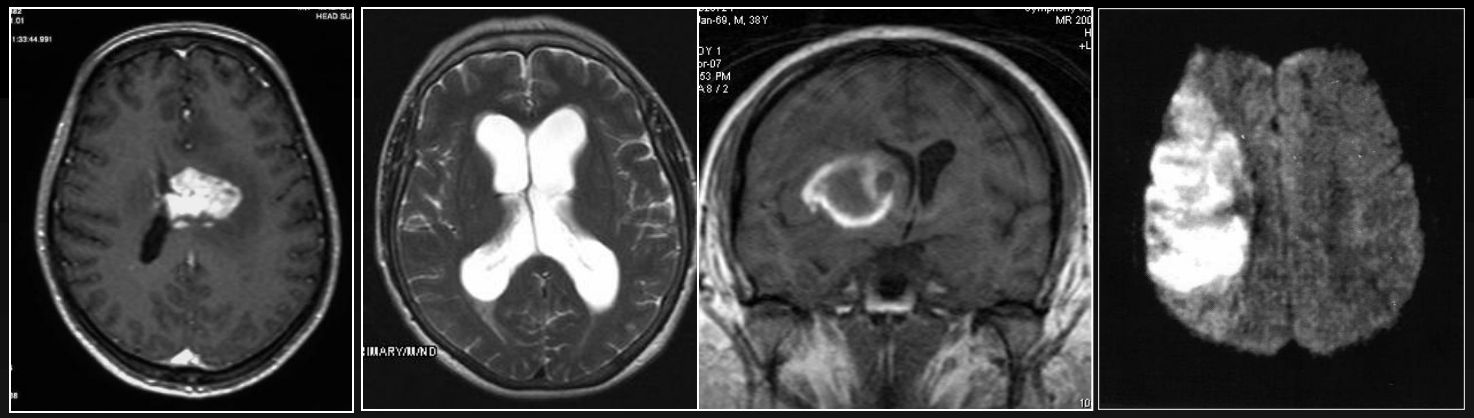

- BOS analizi, biopsi, lab bulgular altın standart olsa da;
  - Nörogörüntüleme önemli
    - Kitle, hidrosefali, hemoraji, iskemi vs ekartasyonu
    - Enflamasyon bulgularını göstermek
    - Lokalizasyonu tanımlamak
    - Enfeksiyon tipini belirlemek
    - Etiyolojik ayırıcı tanıya gitmek
    - Tipik bir görüntüleme paterni ile
      - hızlı terapötik yönetim
    - Tedavi sürecinde ise monitörizasyon

MENENJİTLER

- LP öncesi kitle, ödem gibi kontrendike durumları ekarte etmek için; BT
- Erken evrede gn Kontrastlı BT dahi N
- Vasküler tutuluşa bağlı iskemi varsa (%20)
  - BT ile saptanabilir
- Kafa tabanı, petröz kemik patolojileri BT ile saptanabilir
  - Enf kaynağı; Kırık, Otit/Mastoidit
- İleri evrede hidrosefali, ampiyem veya efüzyon gelişimi açısından BT ile takip yapılabilir

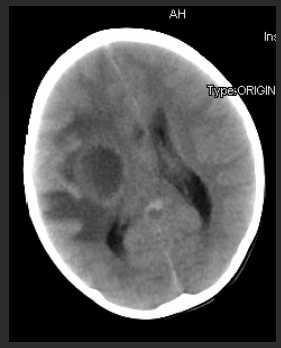

MENENJİTLER

- Kontrastlı MRG;
  - Komplike olmamış bakteriyel menenjit vakalarında rutin bir inceleme değil?
  - Tbc menenjiti tipik olabilir
  - Nöbet ya da fokal defisit gelişen vakalarda kesin endike
    - Serebrit, tüberkülom, vasküler komplikasyon, ventrikülit, abse
      - Difüzyon MR

Meningeal kontrast tutuluşu

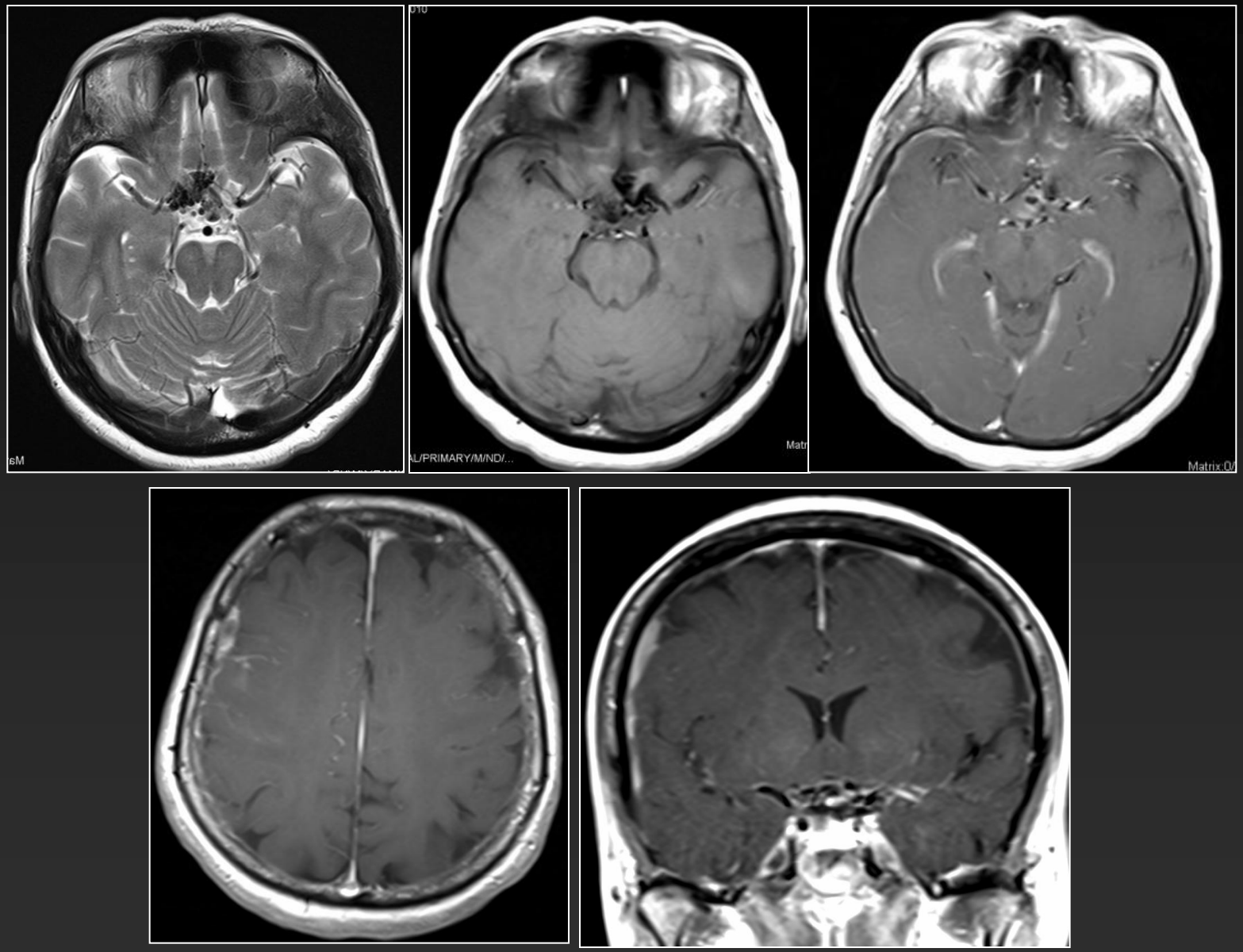

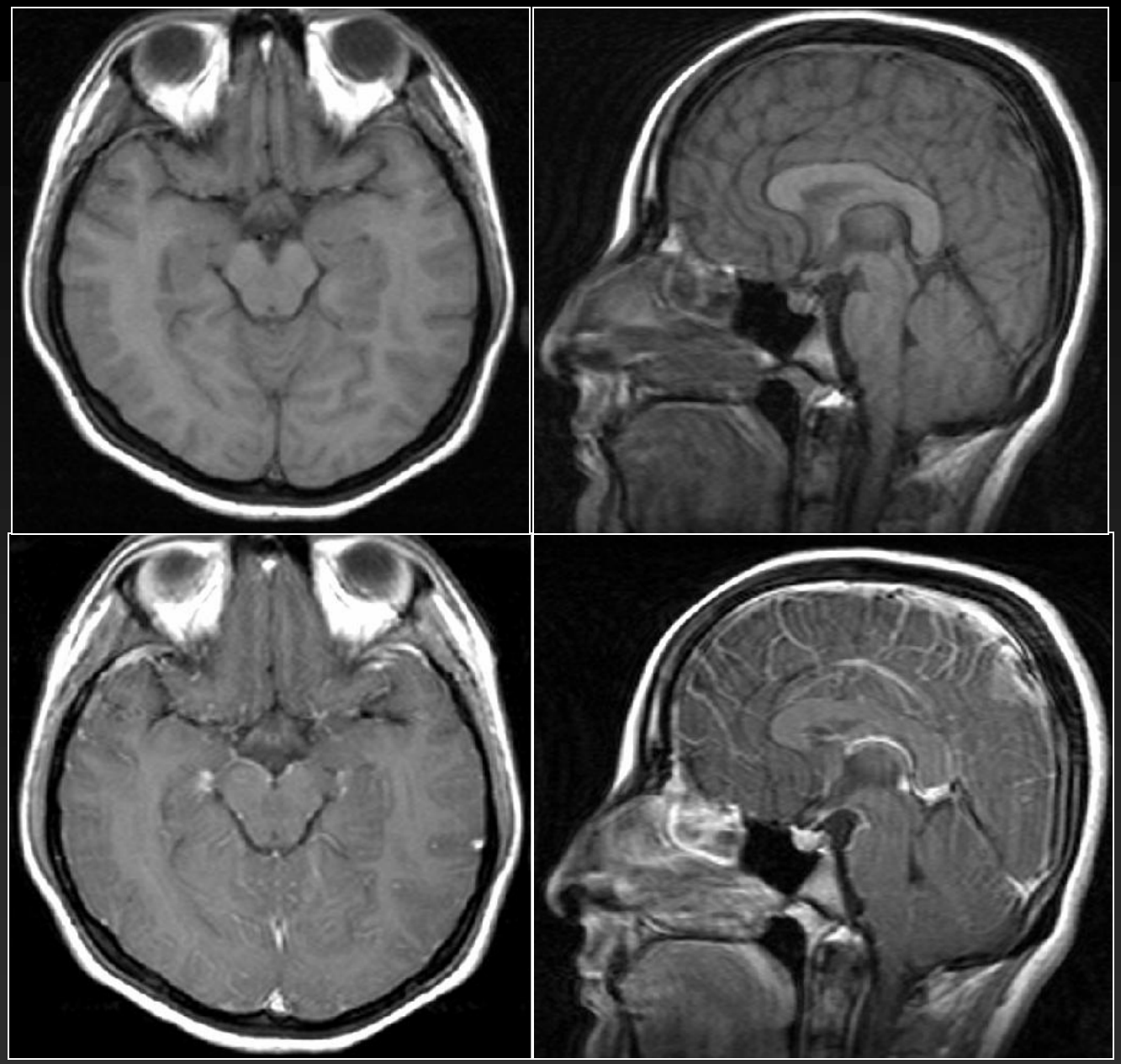

Meningeal kontrast tutuluşu

Meme Ca Leptomeningeal Met

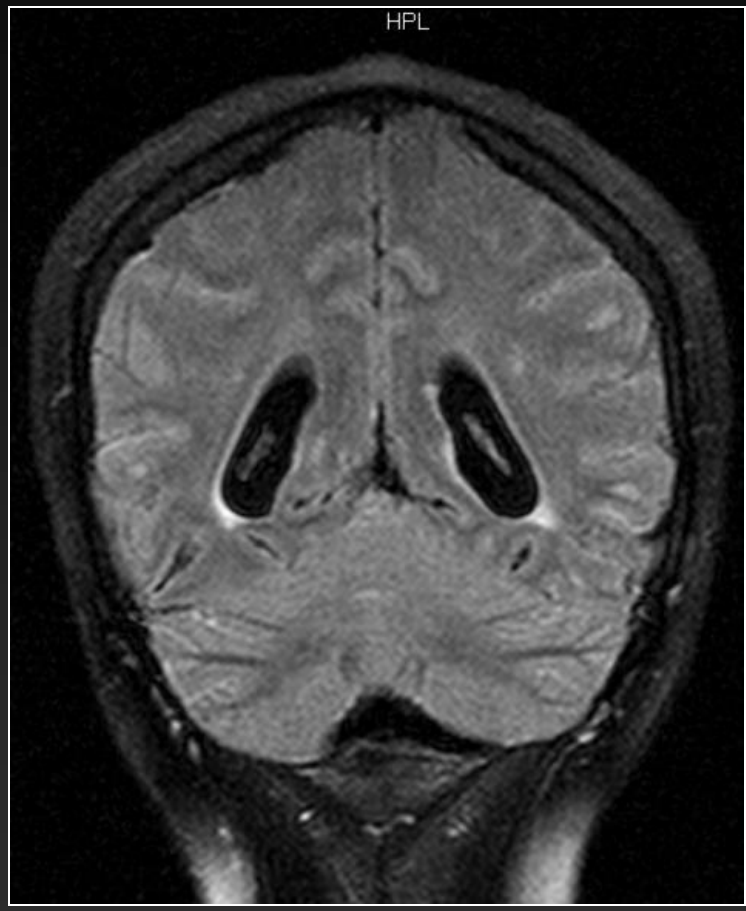

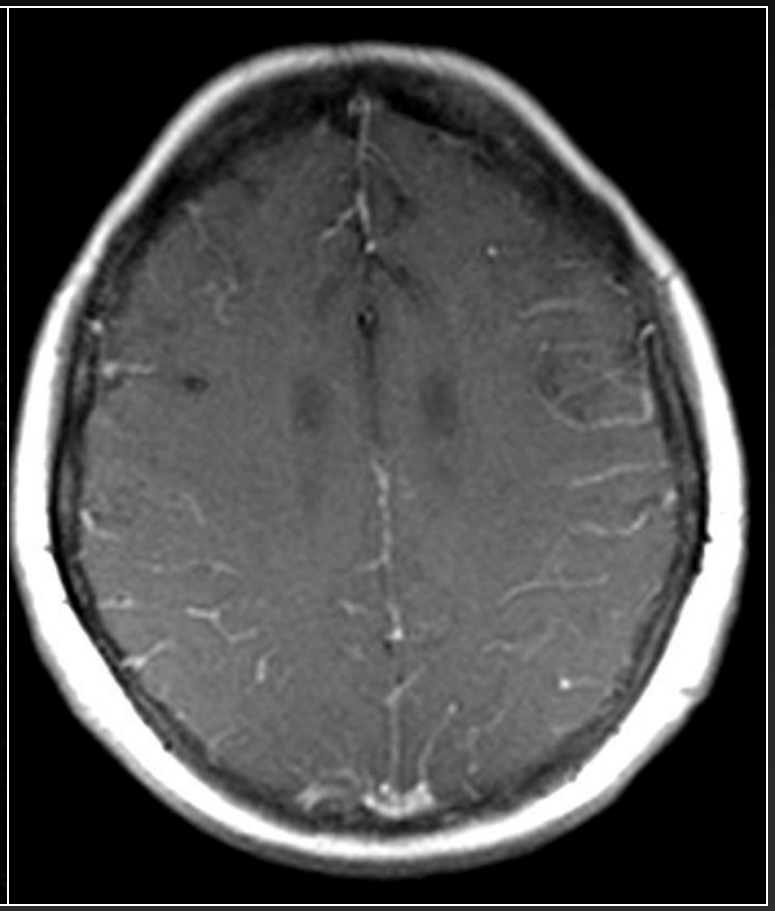

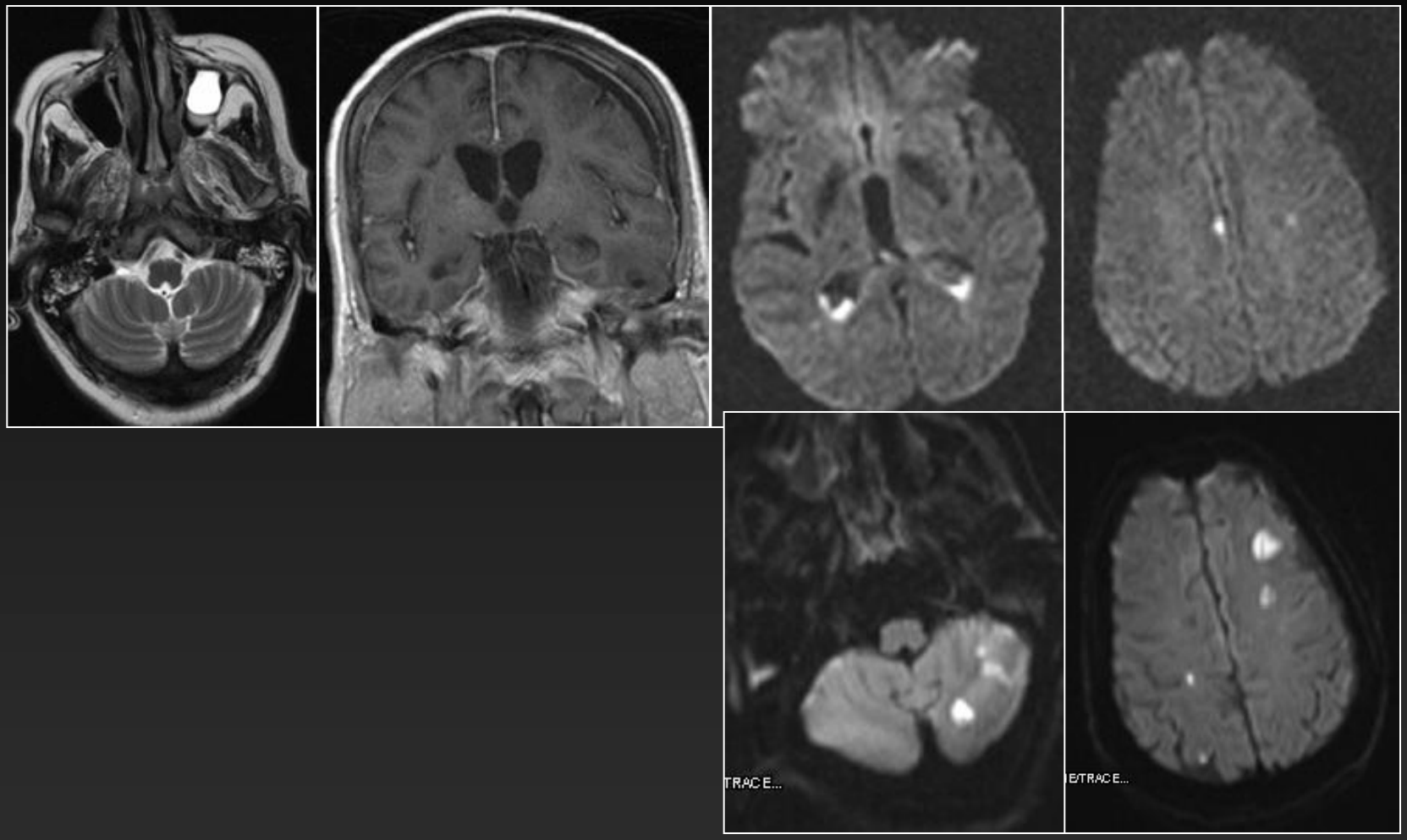

Menenjit-Ventrikülit-Serebrit odakları

TBC

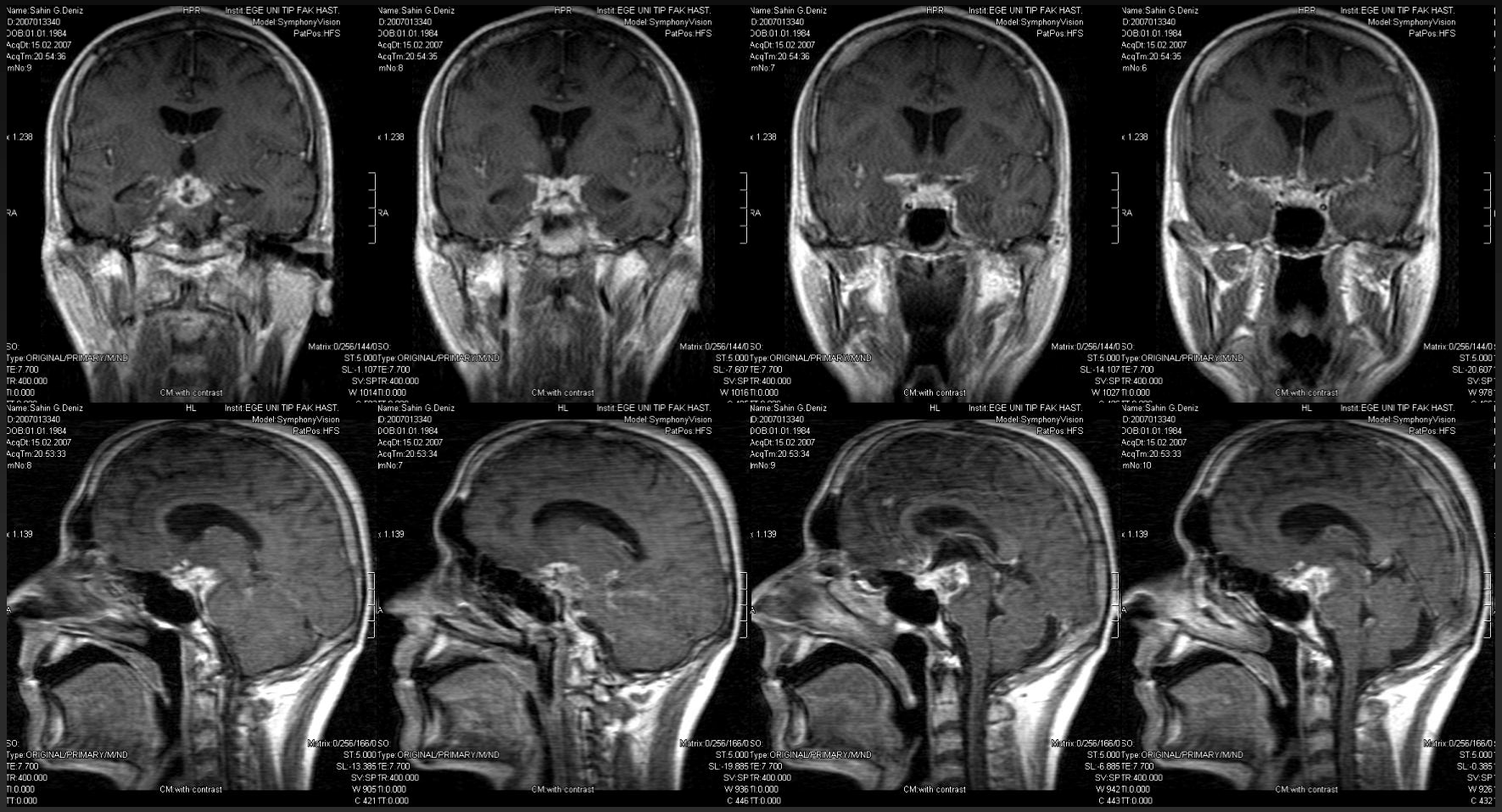
Name:Sahin G.Deniz
ID:2007013340
DOB:01.01.1984
AcqDt:15.02.2007
AcqTm:20.54:36
ImNo:9
HPR
Instit.EGE UNI TIP FAK HAST.
Model:SymphonyVision
PatPos.HFS
Matrix 0/256/144/0 SO:
ST:5.000 Type:ORIGINAL/PRIMARY/M/ND
SL:-1.107 TE:7.700
SV:SP TR:400.000
W:1014 TI:0.000
CM:with contrast
Name:Sahin G.Deniz
ID:2007013340
DOB:01.01.1984
AcqDt:15.02.2007
AcqTm:20.54:35
ImNo:8
HPR
Instit.EGE UNI TIP FAK HAST.
Model:SymphonyVision
PatPos.HFS
Matrix 0/256/144/0 SO:
ST:5.000 Type:ORIGINAL/PRIMARY/M/ND
SL:-7.607 TE:7.700
SV:SP TR:400.000
W:1016 TI:0.000
CM:with contrast
Name:Sahin G.Deniz
ID:2007013340
DOB:01.01.1984
AcqDt:15.02.2007
AcqTm:20.54:36
ImNo:7
HPR
Instit.EGE UNI TIP FAK HAST.
Model:SymphonyVision
PatPos.HFS
Matrix 0/256/144/0 SO:
ST:5.000 Type:ORIGINAL/PRIMARY/M/ND
SL:-14.107 TE:7.700
SV:SP TR:400.000
W:1027 TI:0.000
CM:with contrast
Name:Sahin G.Deniz
ID:2007013340
DOB:01.01.1984
AcqDt:15.02.2007
AcqTm:20.54:35
ImNo:6
HPR
Instit.EGE UNI TIP FAK HAST.
Model:SymphonyVision
PatPos.HFS
CM:with contrast
Name:Sahin G.Deniz
ID:2007013340
DOB:01.01.1984
AcqDt:15.02.2007
AcqTm:20.53:33
ImNo:6
HL
Instit.EGE UNI TIP FAK HAST.
Model:SymphonyVision
PatPos.HFS
Matrix 0/256/166/0 SO:
ST:5.000 Type:ORIGINAL/PRIMARY/M/ND
SL:-13.385 TE:7.700
SV:SP TR:400.000
W:905 TI:0.000
C:421 TT:0.000
CM:with contrast
Name:Sahin G.Deniz
ID:2007013340
DOB:01.01.1984
AcqDt:15.02.2007
AcqTm:20.53:34
ImNo:7
HL
Instit.EGE UNI TIP FAK HAST.
Model:SymphonyVision
PatPos.HFS
Matrix 0/256/166/0 SO:
ST:5.000 Type:ORIGINAL/PRIMARY/M/ND
SL:-19.885 TE:7.700
SV:SP TR:400.000
W:936 TI:0.000
C:446 TT:0.000
CM:with contrast
Name:Sahin G.Deniz
ID:2007013340
DOB:01.01.1984
AcqDt:15.02.2007
AcqTm:20.53:33
ImNo:9
HL
Instit.EGE UNI TIP FAK HAST.
Model:SymphonyVision
PatPos.HFS
Matrix 0/256/166/0 SO:
ST:5.000 Type:ORIGINAL/PRIMARY/M/ND
SL:-6.885 TE:7.700
SV:SP TR:400.000
W:942 TI:0.000
C:443 TT:0.000
CM:with contrast
Name:Sahin G.Deniz
ID:2007013340
DOB:01.01.1984
AcqDt:15.02.2007
AcqTm:20.53:33
ImNo:10
HL
Instit.EGE UNI TIP FAK HAST.
Model:SymphonyVision
PatPos.HFS
CM:with contrast

TBC

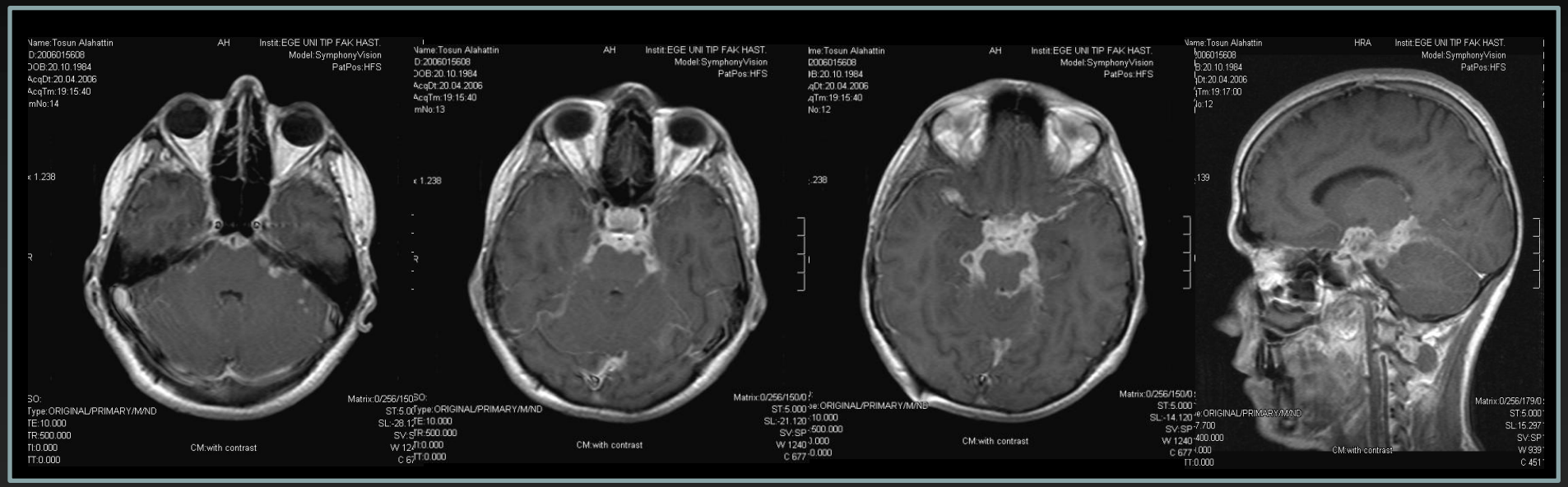
Name:Tosun Alahattin
AH
Instit:EGE UNI TIP FAK HAST.
Model:SymphonyVision
PatPos:HFS
CM:with contrast
HRA

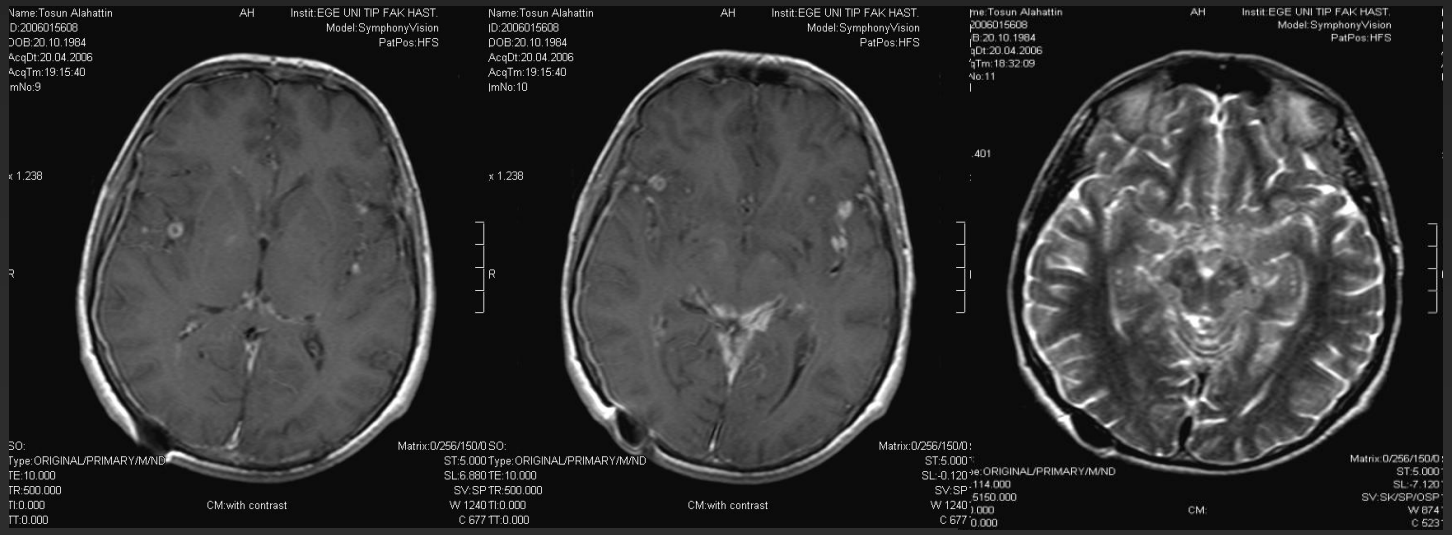
Name:Tosun Alahattin
AH
Instit:EGE UNI TIP FAK HAST.
Model:SymphonyVision
PatPos:HFS
CM:with contrast

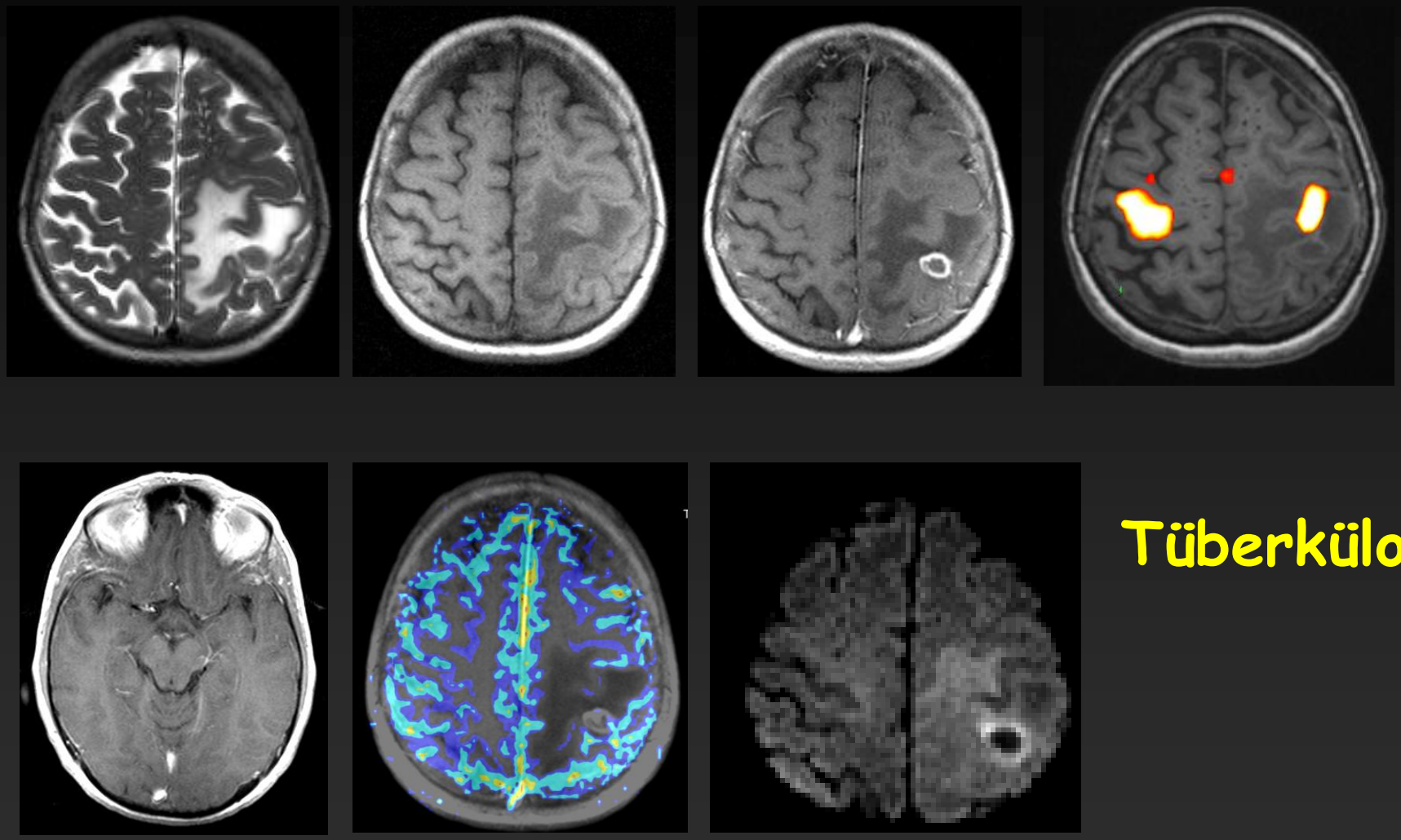

Tüberkülom

PİYOJENİK APSE

- Periferal kontrast tutan kitle
- Ayırıcı tanı;
  - Glioblastom
  - Metastaz
  - Non-piyojenik apse
- Difüzyon MR ve Perfüzyon MR

- Sağ hemisferik lezyon,
- Periferal ödem,
- Periferik kontrastlanma

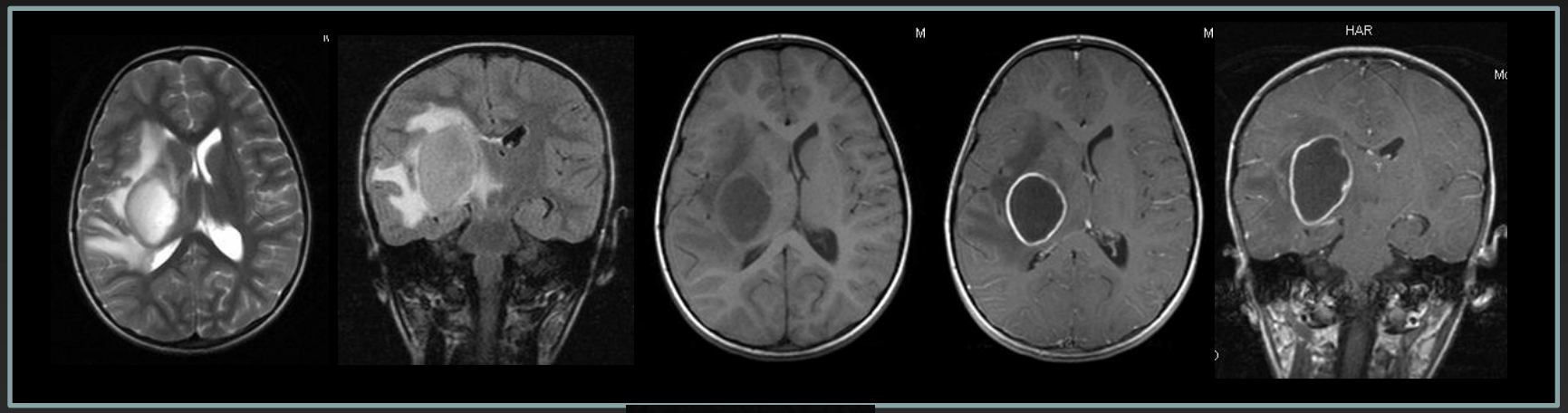

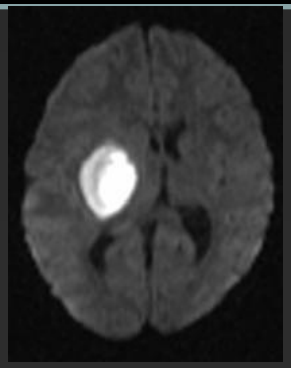

Apse (Piyojenik)

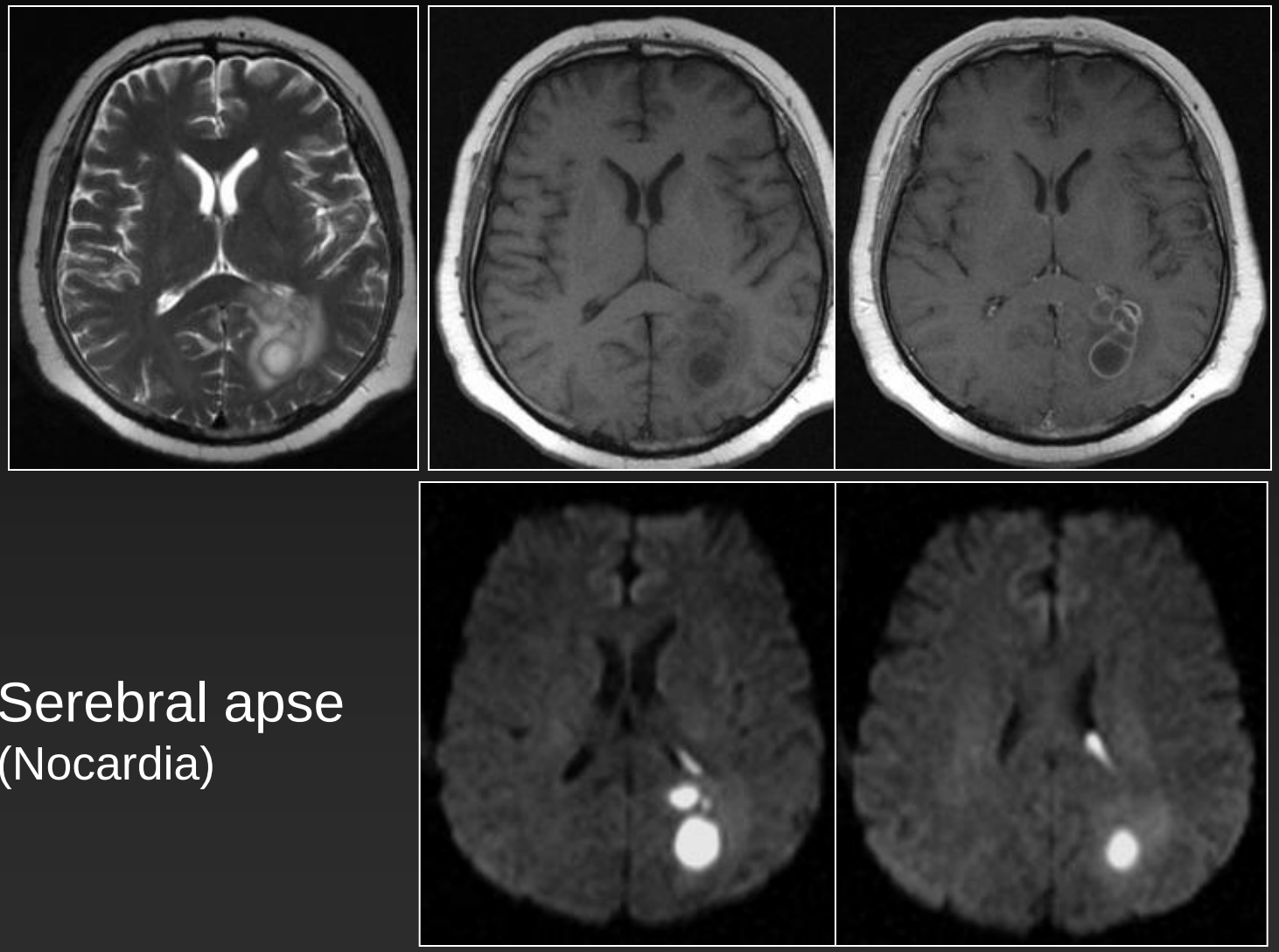

Serebral apse
(Nocardia)

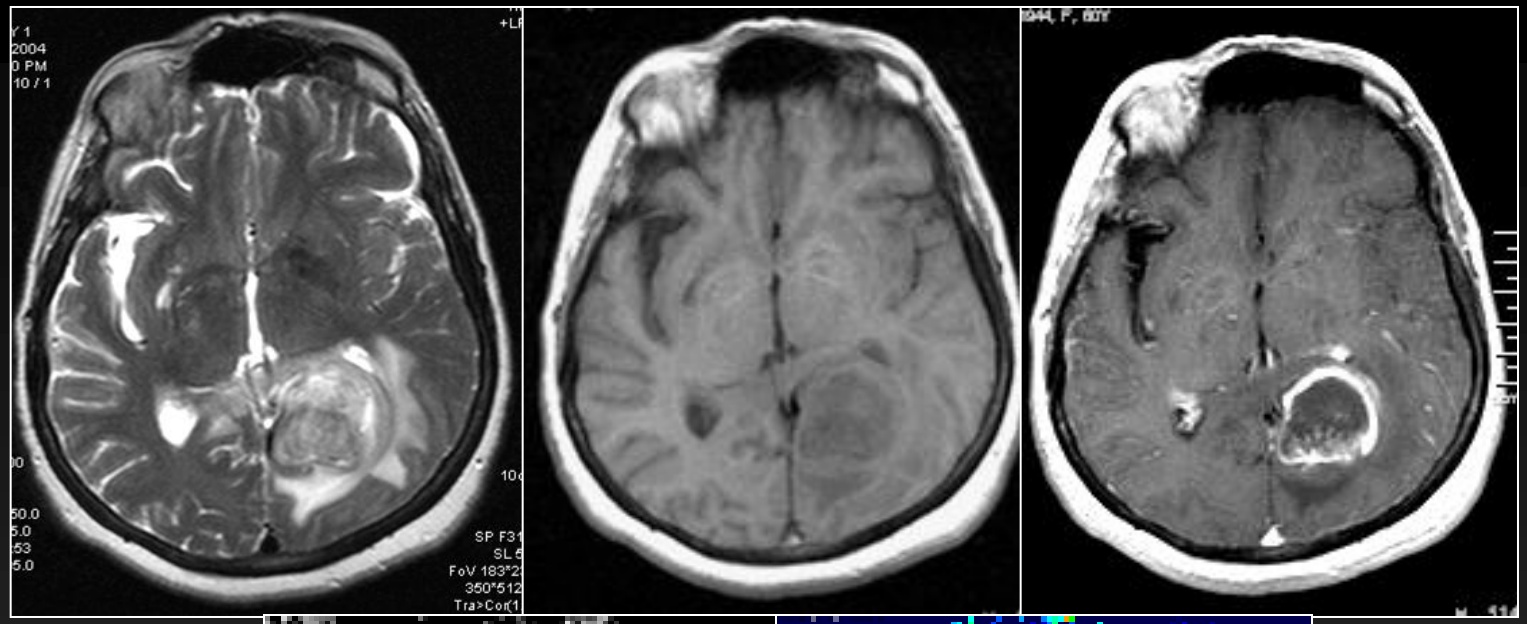

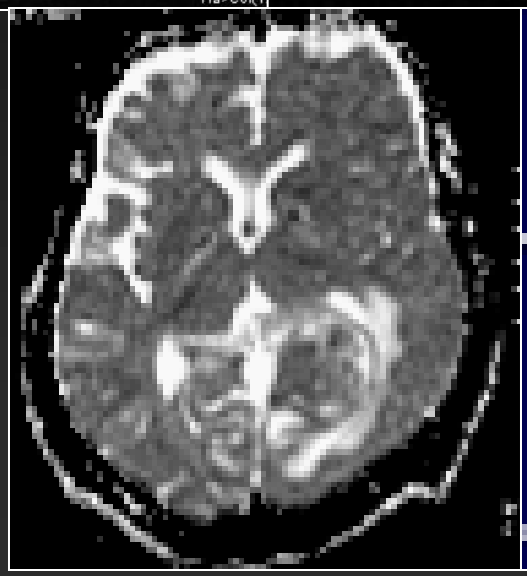

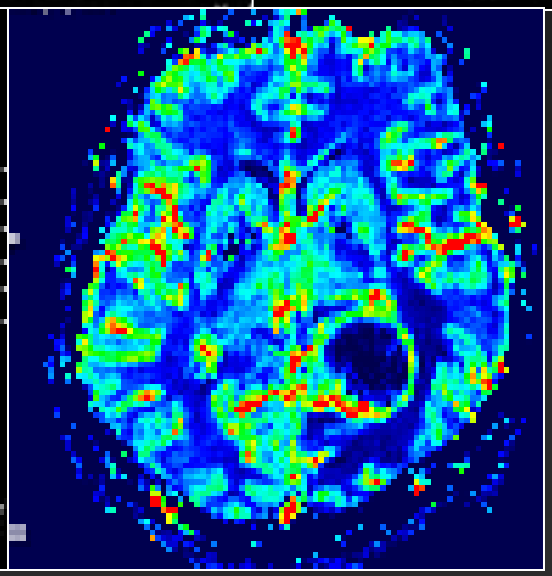

ADC CBV

GBM

Pyojenik Abse: (DWI & PWI)

- Uniform duvar
- Net sınırlı
- T2A hipointens duvar !!
- Santral kısıtlanmış Dif.
- İnce duvar (<1cm)
- Periferal ödem
- Kapsülde düşük PERF.

Apse vs Tm

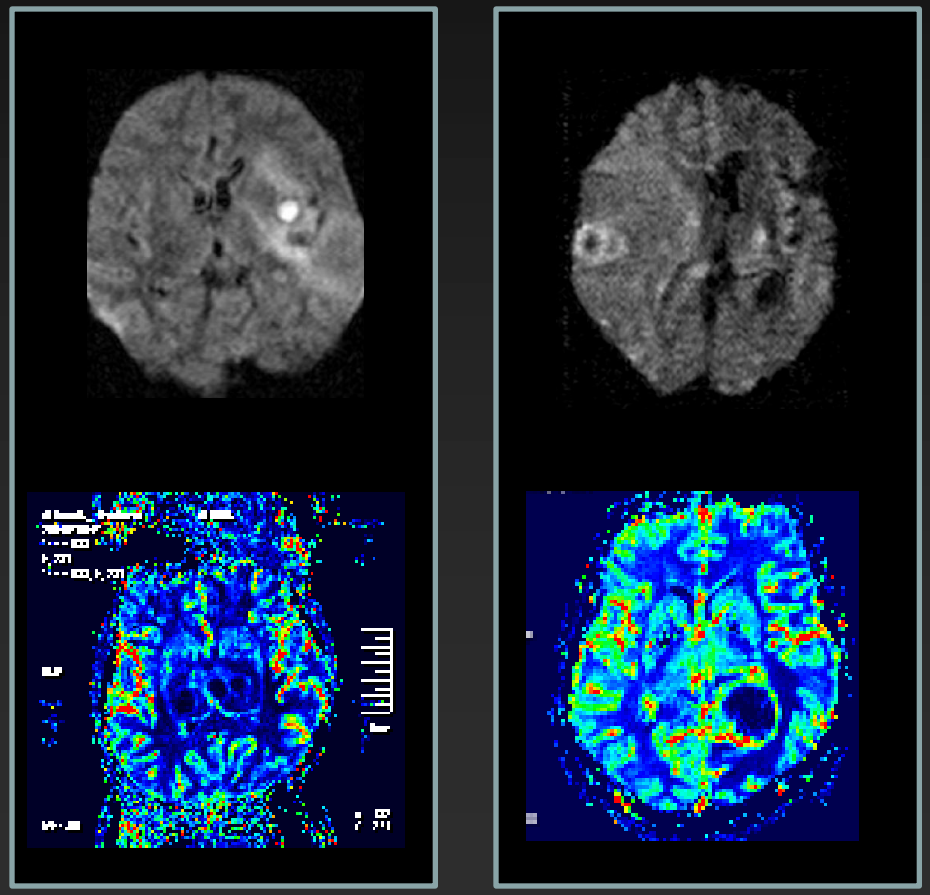

TOKSOPLAZMOZ

- Özellikle immünsüprese hastalarda
  - Fırsatçı enfeksiyon
- Multipl kontrast tutan lezyon
- Ayırıcı tanı; Difüzyon ve Perfüzyon MR
  - Metastaz
  - Lenfoma

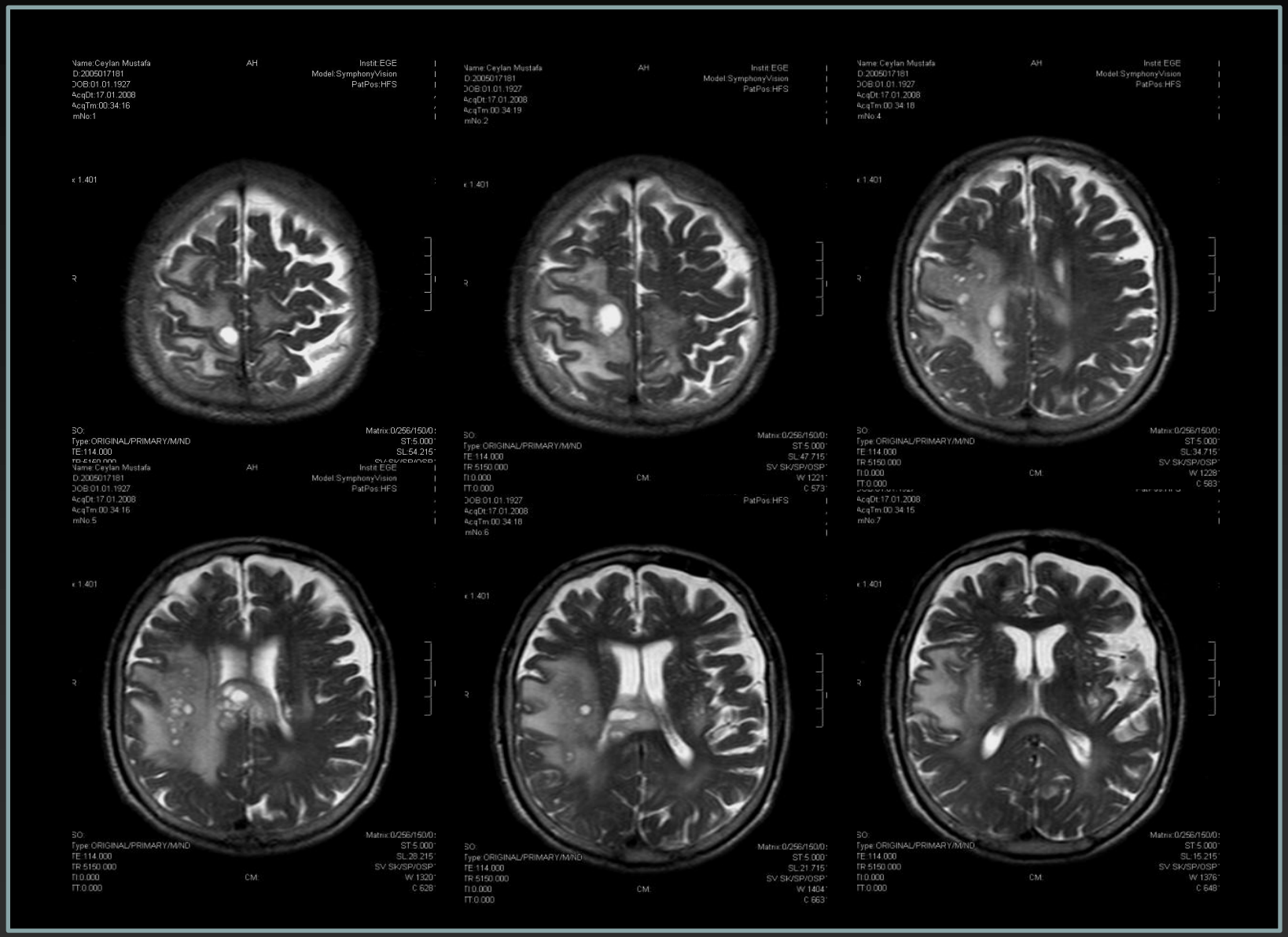
Name:Ceylan Mustafa
D:2005017181
DOB:01.01.1927
AcqDt:17.01.2008
AcqTm:00:34:16
mNo:1
AH
Instit:EGE
Model:SymphonyVision
PatPos:HFS
x 1.401
R
SO:
Type:ORIGINAL/PRIMARY/M/ND
TE:114.000
Matrix:0/256/150/0:
ST:5.000
SL:54.215
Name:Ceylan Mustafa
D:2005017181
DOB:01.01.1927
AcqDt:17.01.2008
AcqTm:00:34:19
mNo:2
AH
Instit:EGE
Model:SymphonyVision
PatPos:HFS
x 1.401
R
SO:
Type:ORIGINAL/PRIMARY/M/ND
TE:114.000
TR:5150.000
TI:0.000
TT:0.000
CM:
Matrix:0/256/150/0:
ST:5.000
SL:47.715
SV:SK/SP/OSP
W:1221
C:573
DOB:01.01.1927
AcqDt:17.01.2008
AcqTm:00:34:18
mNo:6
PatPos:HFS
Name:Ceylan Mustafa
D:2005017181
DOB:01.01.1927
AcqDt:17.01.2008
AcqTm:00:34:18
mNo:4
AH
Instit:EGE
Model:SymphonyVision
PatPos:HFS
x 1.401
R
SO:
Type:ORIGINAL/PRIMARY/M/ND
TE:114.000
TR:5150.000
TI:0.000
TT:0.000
CM:
Matrix:0/256/150/0:
ST:5.000
SL:34.715
SV:SK/SP/OSP
W:1228
C:583
AcqDt:17.01.2008
AcqTm:00:34:15
mNo:7
Name:Ceylan Mustafa
D:2005017181
DOB:01.01.1927
AcqDt:17.01.2008
AcqTm:00:34:16
mNo:5
AH
Instit:EGE
Model:SymphonyVision
PatPos:HFS
x 1.401
R
SO:
Type:ORIGINAL/PRIMARY/M/ND
TE:114.000
TR:5150.000
TI:0.000
TT:0.000
CM:
Matrix:0/256/150/0:
ST:5.000
SL:28.215
SV:SK/SP/OSP
W:1320
C:628
x 1.401
R
SO:
Type:ORIGINAL/PRIMARY/M/ND
TE:114.000
TR:5150.000
TI:0.000
TT:0.000
CM:
Matrix:0/256/150/0:
ST:5.000
SL:21.715
SV:SK/SP/OSP
W:1404
C:663
x 1.401
R
SO:
Type:ORIGINAL/PRIMARY/M/ND
TE:114.000
TR:5150.000
TI:0.000
TT:0.000
CM:
Matrix:0/256/150/0:
ST:5.000
SL:15.215
SV:SK/SP/OSP
W:1376
C:648

Name:Ceylan Mustafa
AH
Instit:EGE
D:2005017181
Model:SymphonyVision
DOB:01.01.1927
PatPos:HFS
AcqDt:17.01.2008
AcqTm:00:35:56
mNo:1
Type:ORIGINAL/PRIMARY/M/ND
TE:10.000
TR:500.000
TI:0.000
CM:
mNo:3
mNo:4
mNo:5
mNo:6
mNo:7

Toxoplasmosis

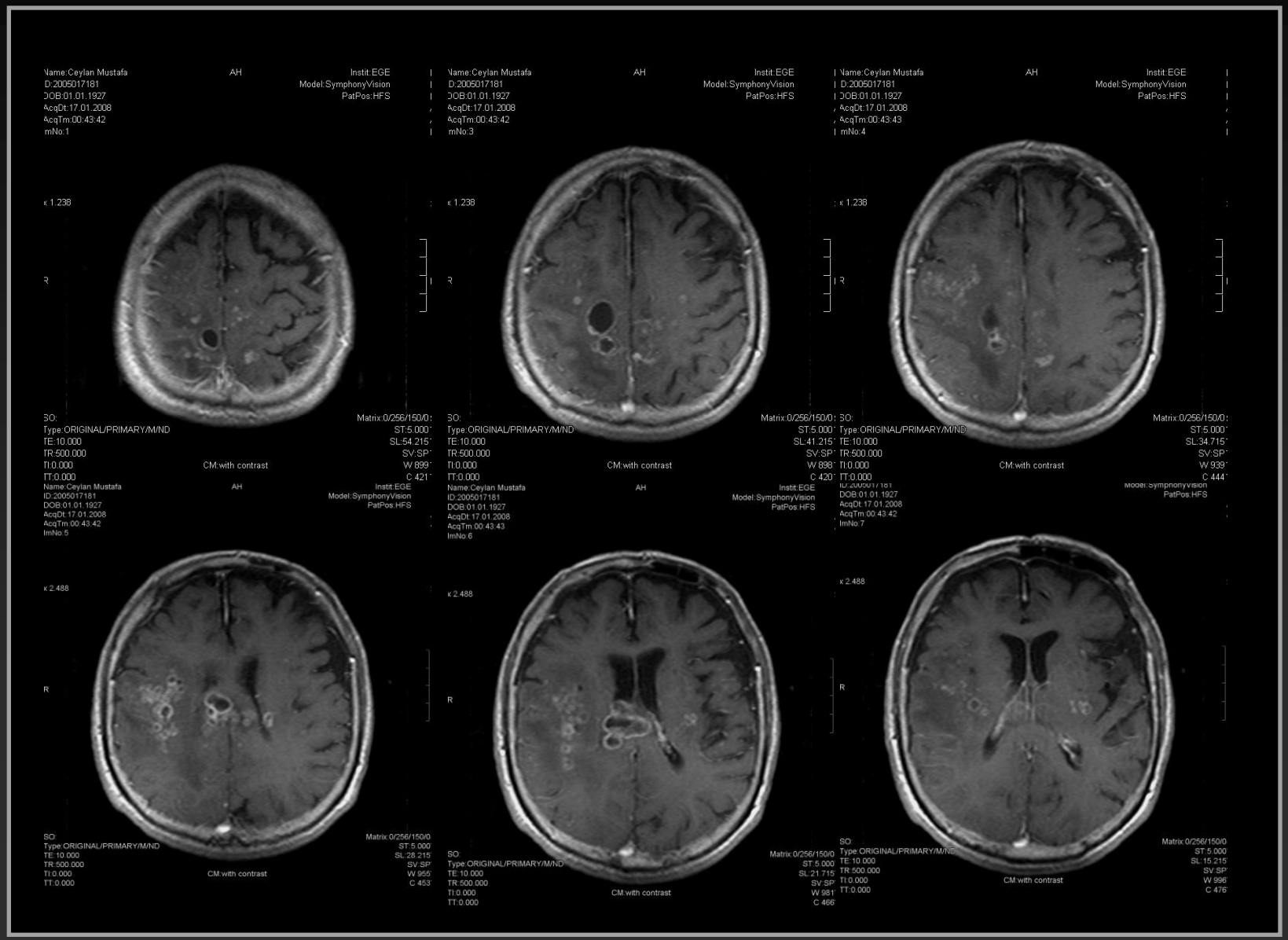

4.11.201

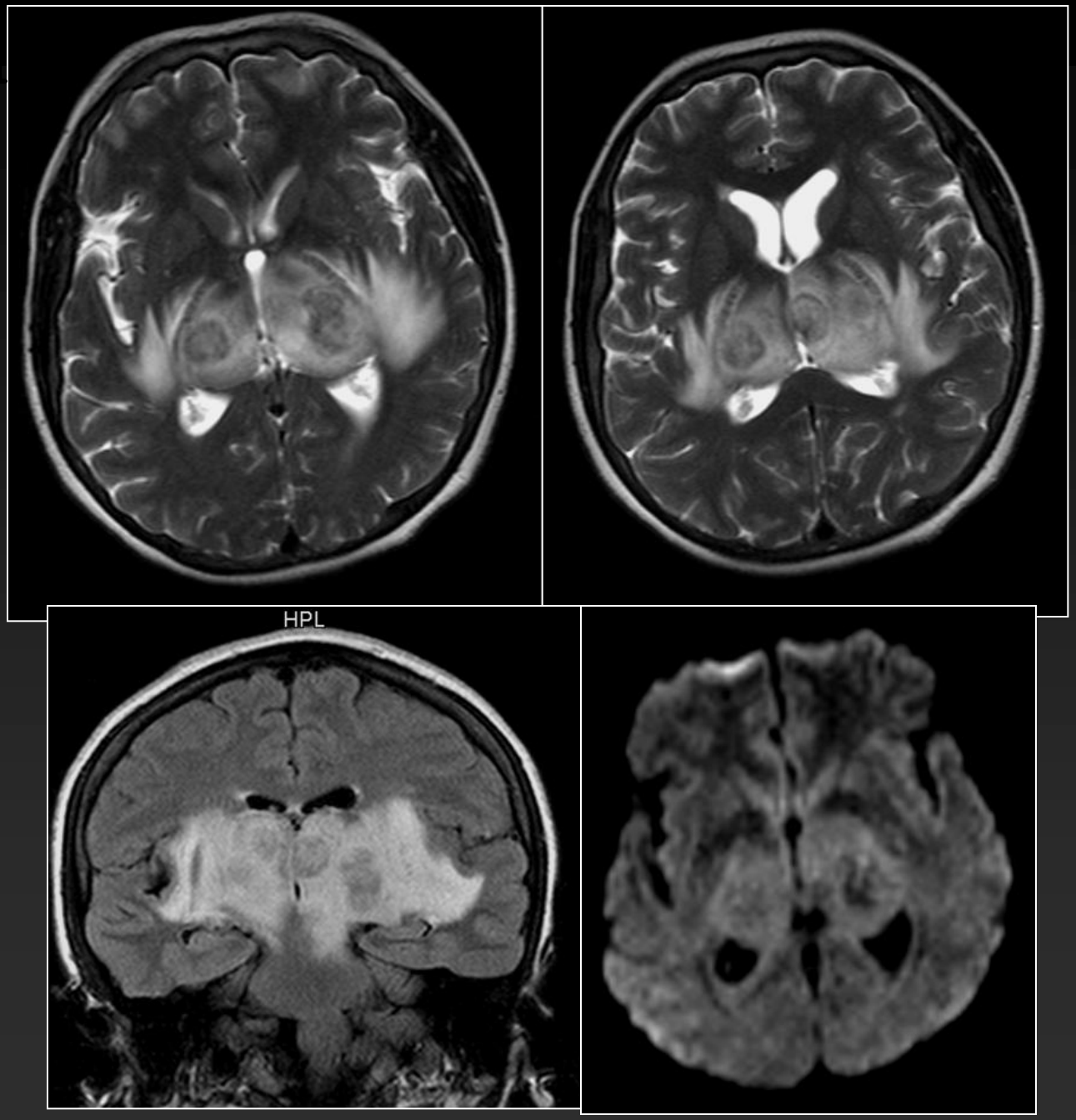

4.11.2011

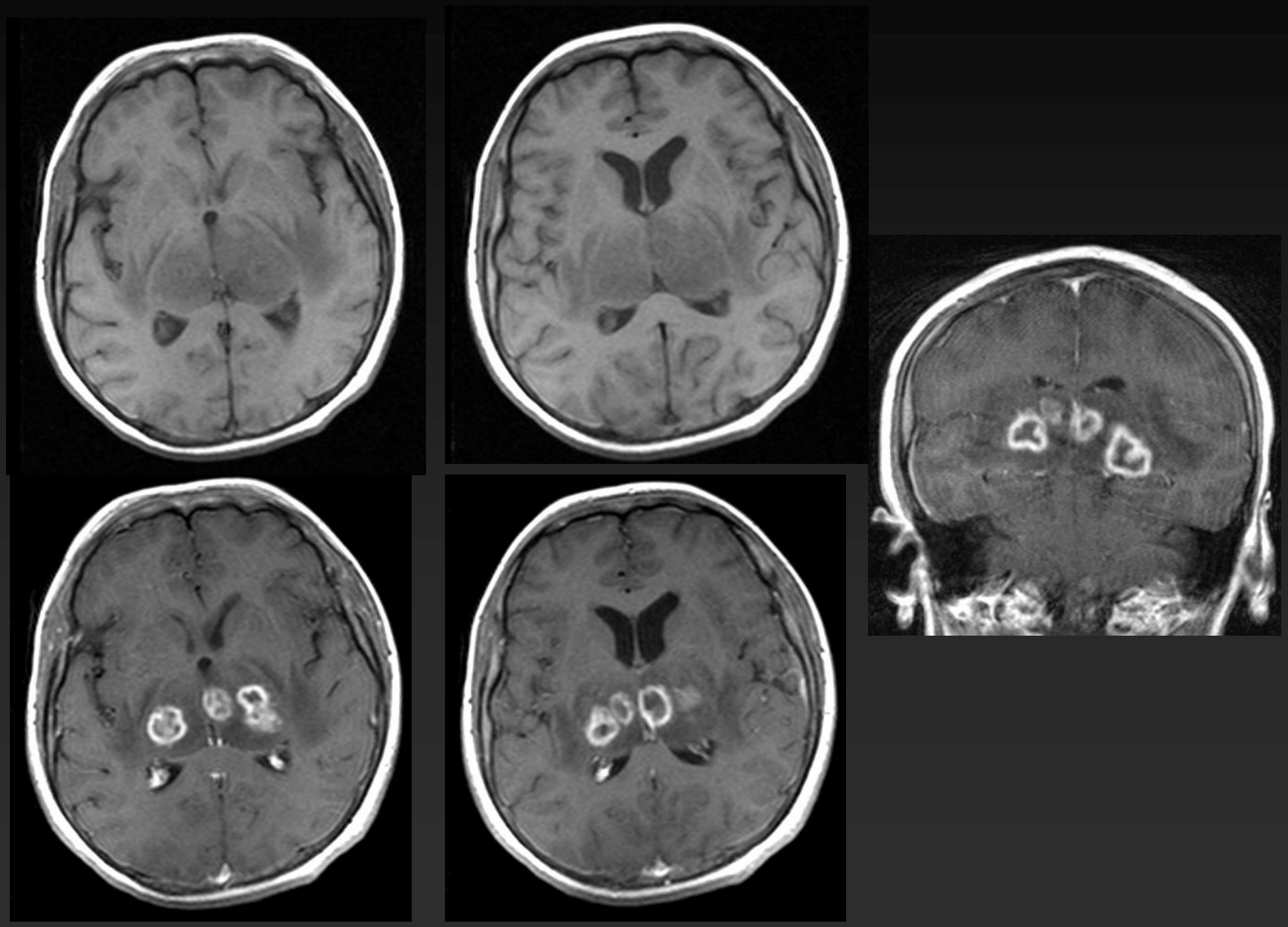

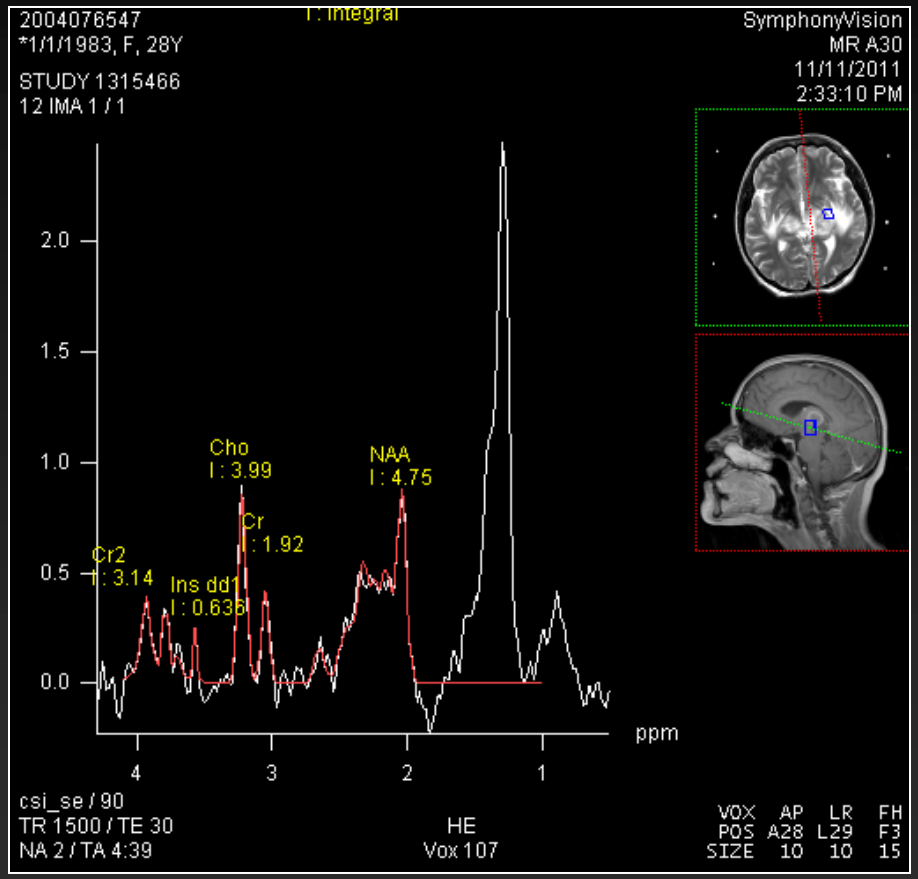
2004076547
*1/1/1983, F, 28Y
STUDY 1315466
12 IMA 1 / 1
I: Integral
SymphonyVision
MR A30
11/11/2011
2:33:10 PM
2.0
1.5
1.0
0.5
0.0
Cho
I : 3.99
NAA
I : 4.75
Cr
: 1.92
Cr2
I : 3.14
Ins dd1
I : 0.635
ppm
4
3
2
1
csi_se / 90
TR 1500 / TE 30
NA 2 / TA 4:39
HE
Vox 107
VOX AP LR FH
POS A28 L29 F3
SIZE 10 10 15

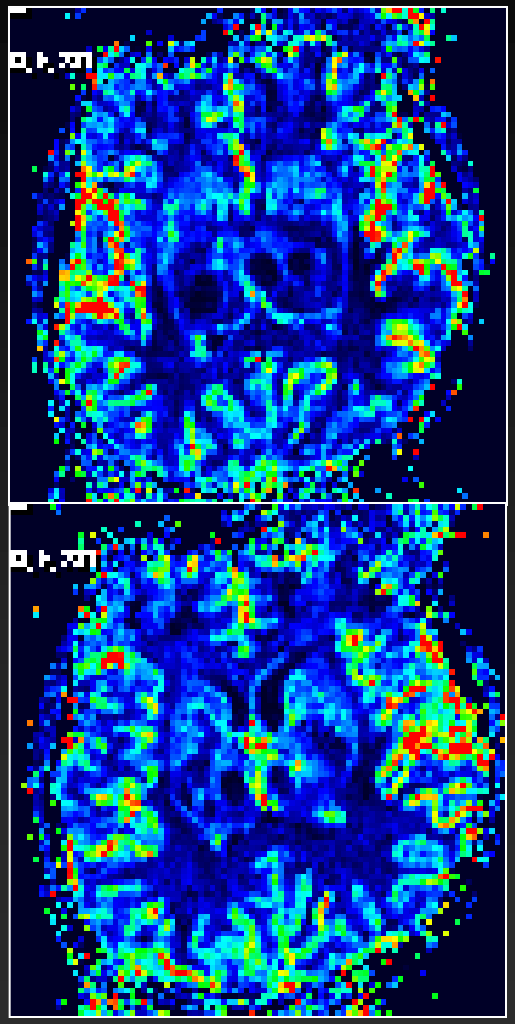

Toxoplasmosis

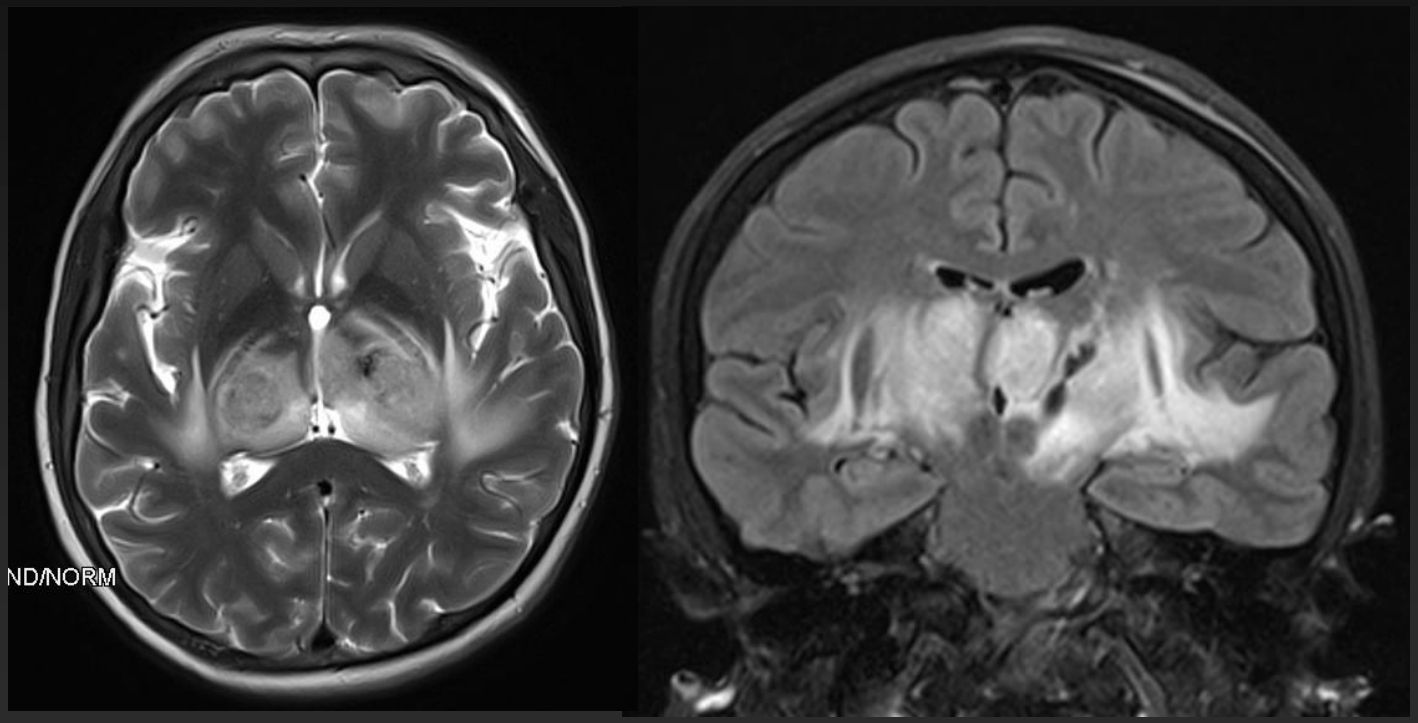

Fungal Enfeksiyonlar

- Ayırıcı tanı güç hasta grubu
- İmmünsüprese hastalar (Diabet, lösemi, lenfoma, AIDS, organ Tx)
- Cryptococcosis, Aspergillosis, Mucormycosis, candidiasis

Kriptokok enfeksiyonu

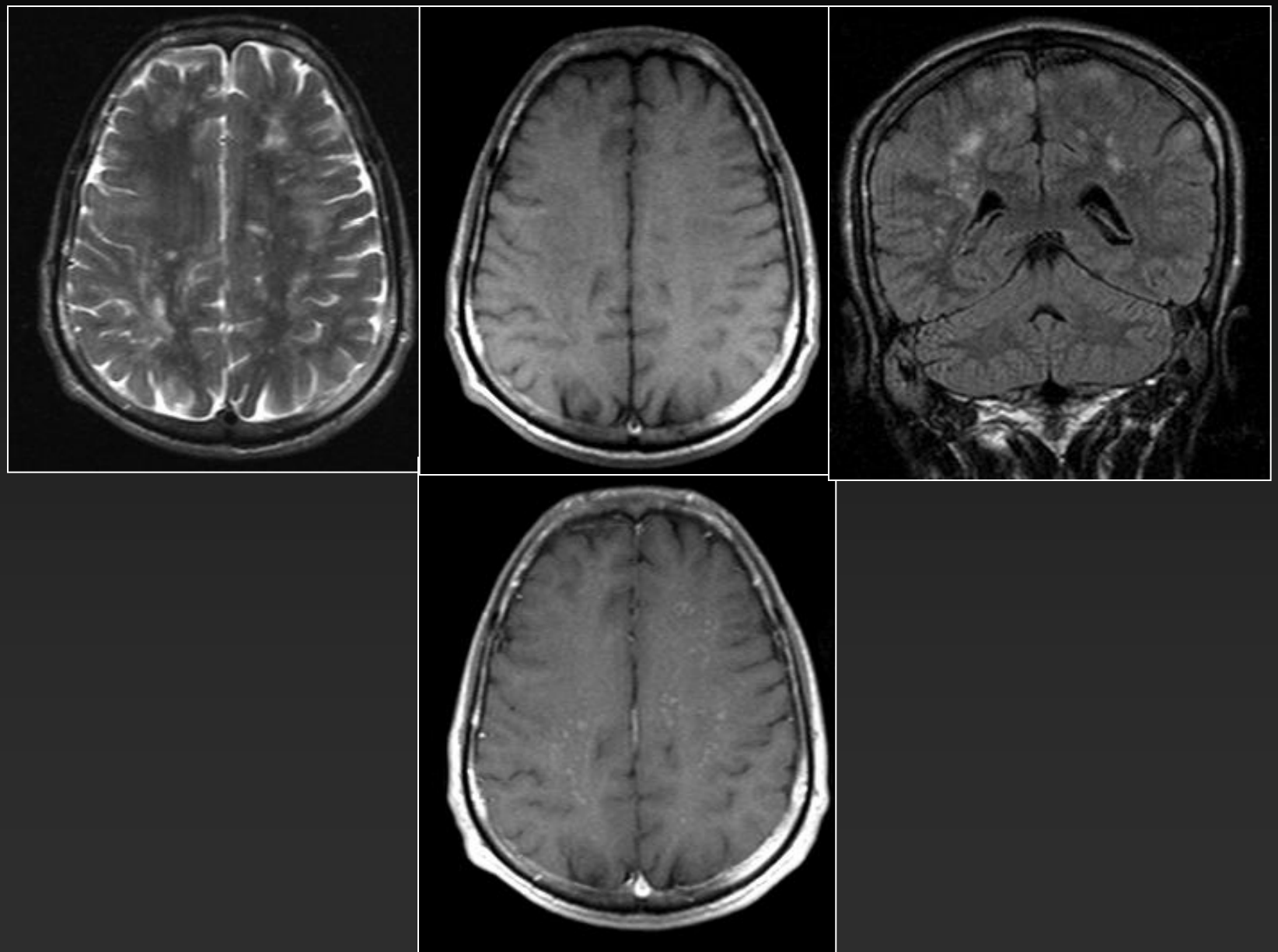

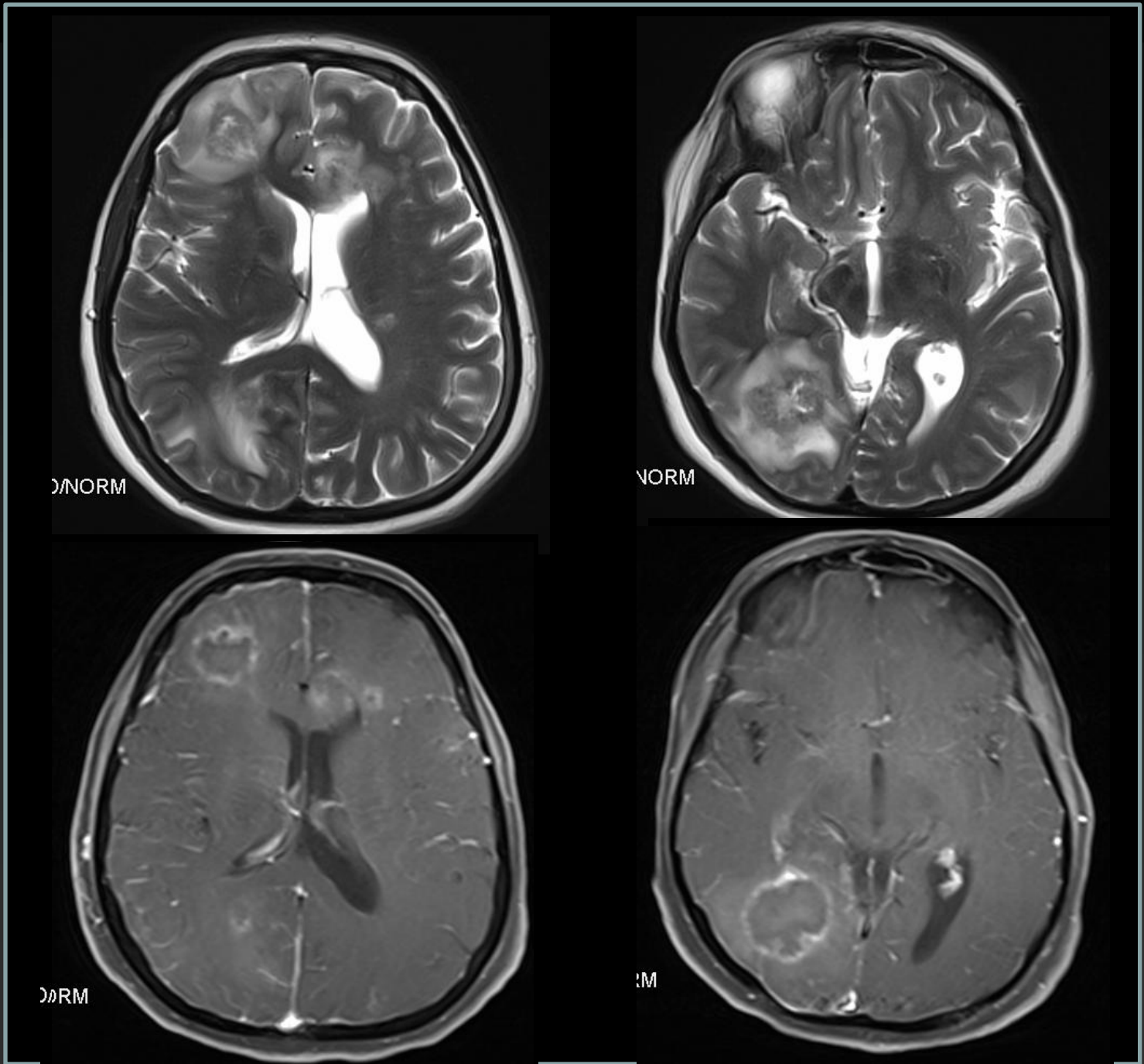
D/NORM
NORM
D/RM
M

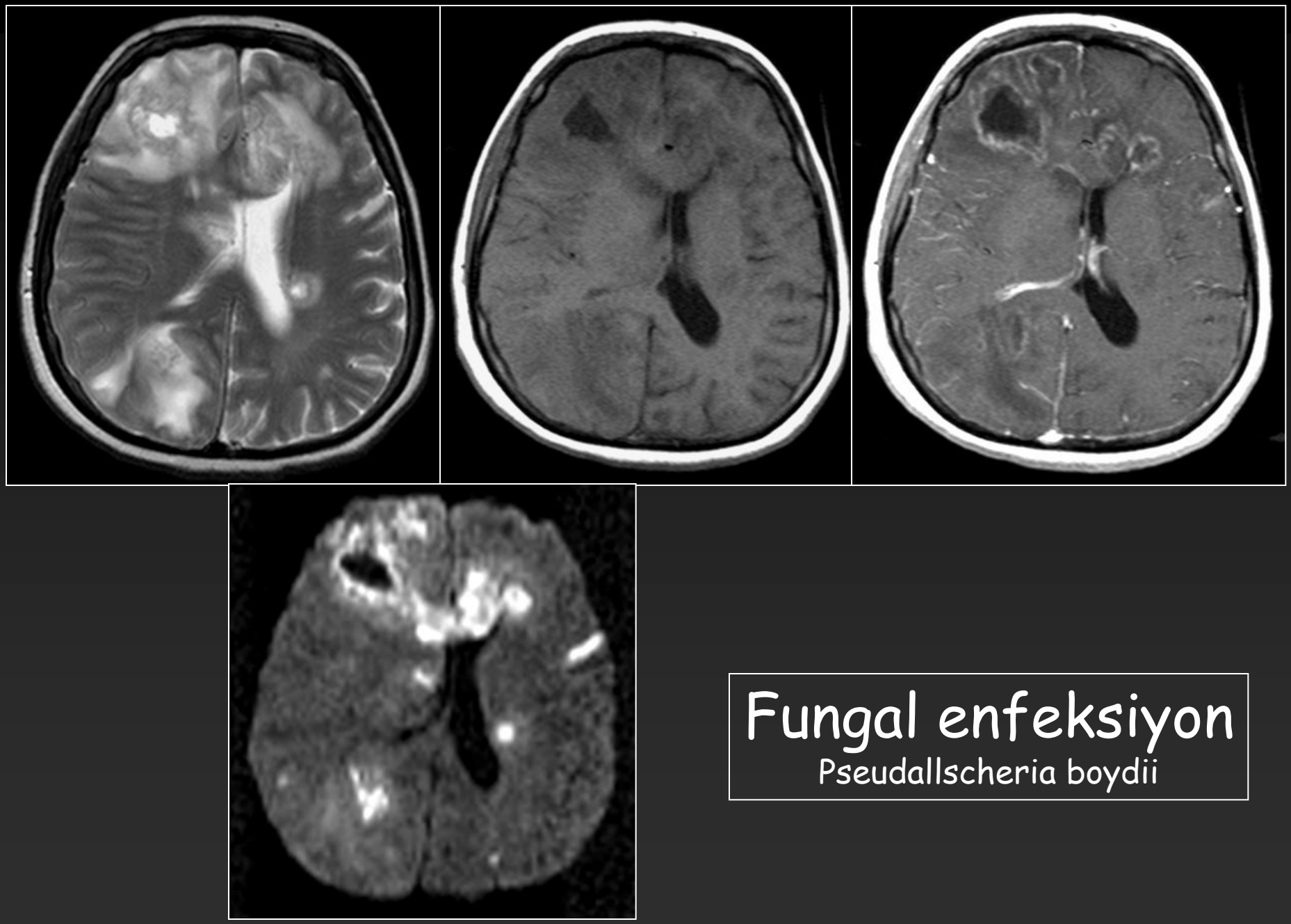

Fungal enfeksiyon

Pseudallscheria boydii

MUCOR

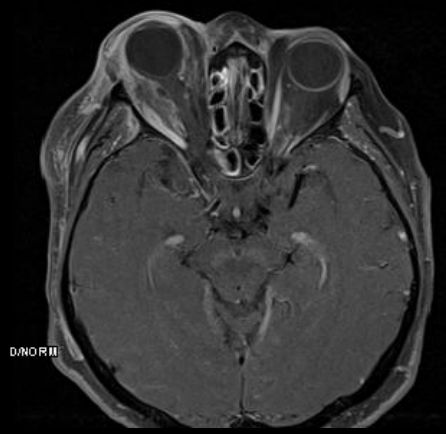

22.7.2013

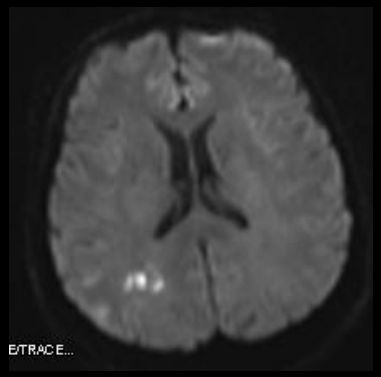

02.8.2013

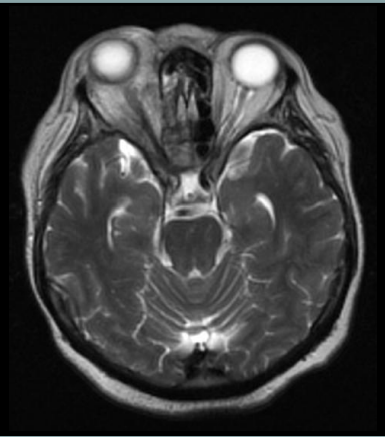

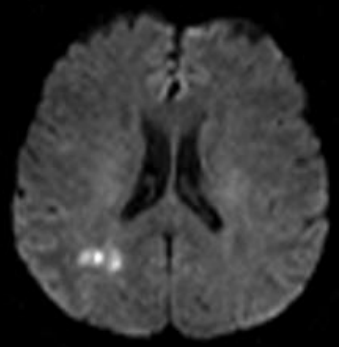

15.8.2013

Viral Menenjitler

- Tanı genellikle klinik ve lab testlerle
- Görüntüleme sıklıkla normal
- Bazen meningeal kontrast tutuluşu

Viral ansefalitler

- HSV-1 / HSV-2
- Ansefalit / Kranial nöritler
- EEG karakteristik
- Mortalite >70%
- T2 ve FLAIR
- DWI: kısıtlanmış difüzyon

HSV

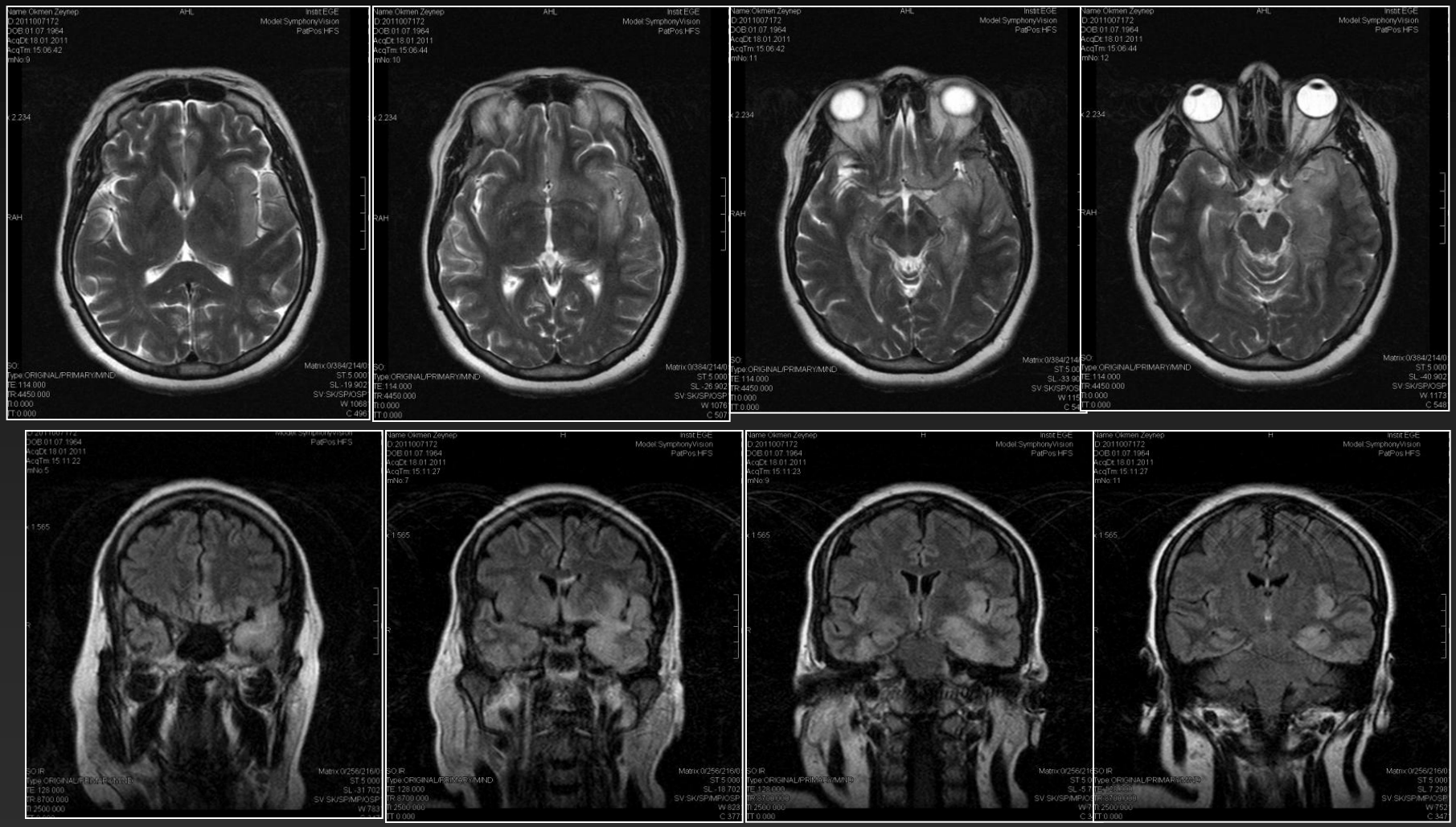

HSV

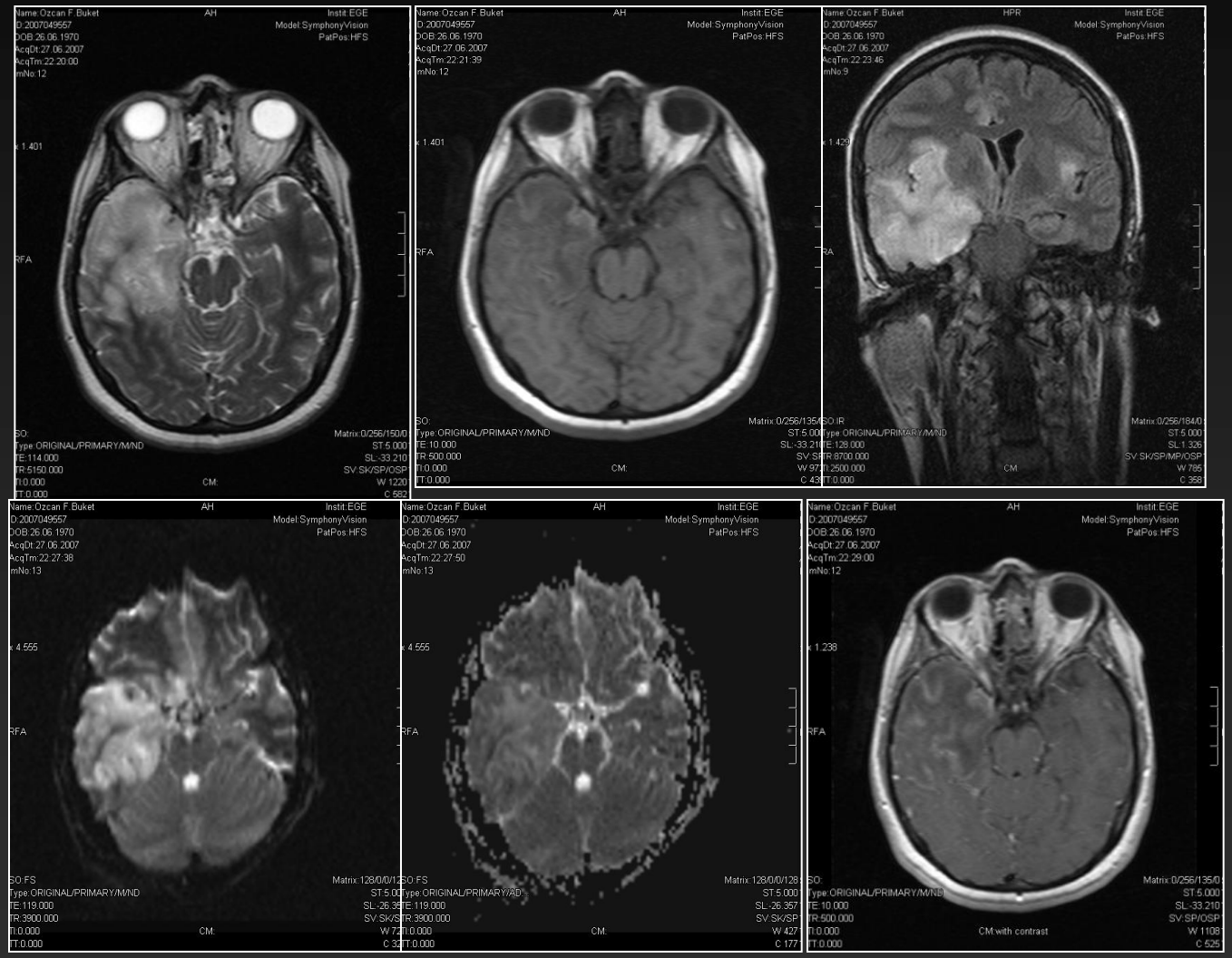
Name:Ozcan F.Buket
AH
Instit:EGE
ID:2007049557
Model:SymphonyVision
DOB:26.06.1970
PatPos:HFS
AcqDt:27.06.2007
AcqTm:22:20.00
ImNo:12
RFA
SO:
Type:ORIGINAL/PRIMARY/M/ND
TE:114.000
TR:5150.000
TI:0.000
TT:0.000
CM:
Name:Ozcan F.Buket
AH
Instit:EGE
ID:2007049557
Model:SymphonyVision
DOB:26.06.1970
PatPos:HFS
AcqDt:27.06.2007
AcqTm:22:21:39
ImNo:12
RFA
SO:
Type:ORIGINAL/PRIMARY/M/ND
TE:10.000
TR:500.000
TI:0.000
TT:0.000
CM:
Name:Ozcan F.Buket
HPR
Instit:EGE
ID:2007049557
Model:SymphonyVision
DOB:26.06.1970
PatPos:HFS
AcqDt:27.06.2007
AcqTm:22:23:46
ImNo:9
SO:IR
Type:ORIGINAL/PRIMARY/M/ND
TE:128.000
TR:8700.000
TI:2500.000
TT:0.000
CM:
Name:Ozcan F.Buket
AH
Instit:EGE
ID:2007049557
Model:SymphonyVision
DOB:26.06.1970
PatPos:HFS
AcqDt:27.06.2007
AcqTm:22:27:38
ImNo:13
SO:FS
Type:ORIGINAL/PRIMARY/M/ND
TE:119.000
TR:3900.000
TI:0.000
TT:0.000
CM:
Name:Ozcan F.Buket
AH
Instit:EGE
ID:2007049557
Model:SymphonyVision
DOB:26.06.1970
PatPos:HFS
AcqDt:27.06.2007
AcqTm:22:27:50
ImNo:13
SO:FS
Type:ORIGINAL/PRIMARY/AD
TE:119.000
TR:3900.000
TI:0.000
TT:0.000
CM:
Name:Ozcan F.Buket
AH
Instit:EGE
ID:2007049557
Model:SymphonyVision
DOB:26.06.1970
PatPos:HFS
AcqDt:27.06.2007
AcqTm:22:29:00
ImNo:12
SO:
Type:ORIGINAL/PRIMARY/M/ND
TE:10.000
TR:500.000
TI:0.000
TT:0.000
CM:with contrast

Serebellit

Creutzfeldt- Jakob

- Hızlı progresif demans, myokloni, ataksi
- 1y Mortalite 80%
- EEG : Karakteristik peridokik keskin dalgalar
- Sporadik , Iatrojenik, nvCJD
- Simetrik hiperintensite
  - caudate & putamen & dağınık lezyonlar serebral korteks; DWI & FLAIR
- Kontrast tutuluşu yok
- NvCJD : talamik simetrik T2 hiperintensite

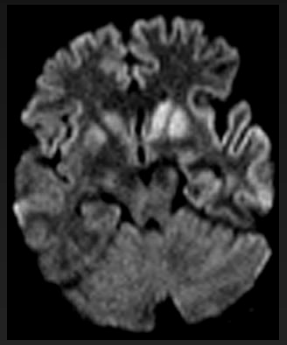

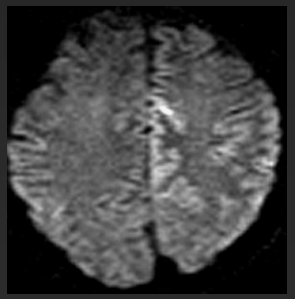

Jakob - Creutzfeld

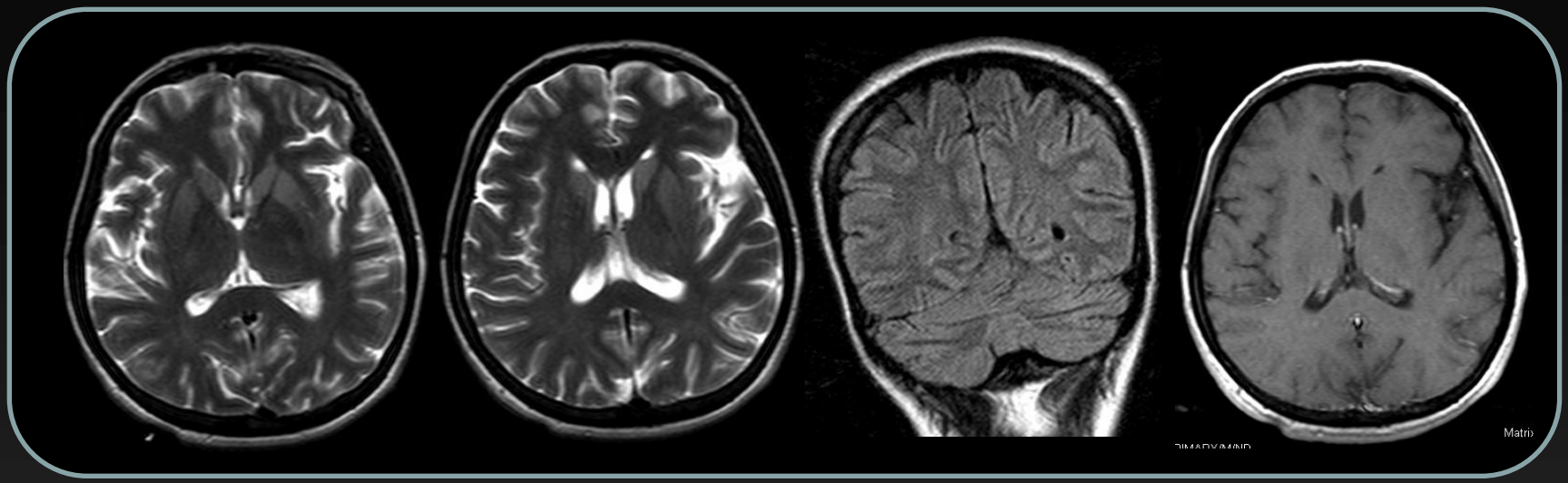

Difüzyon ağırlıklı görüntüleme

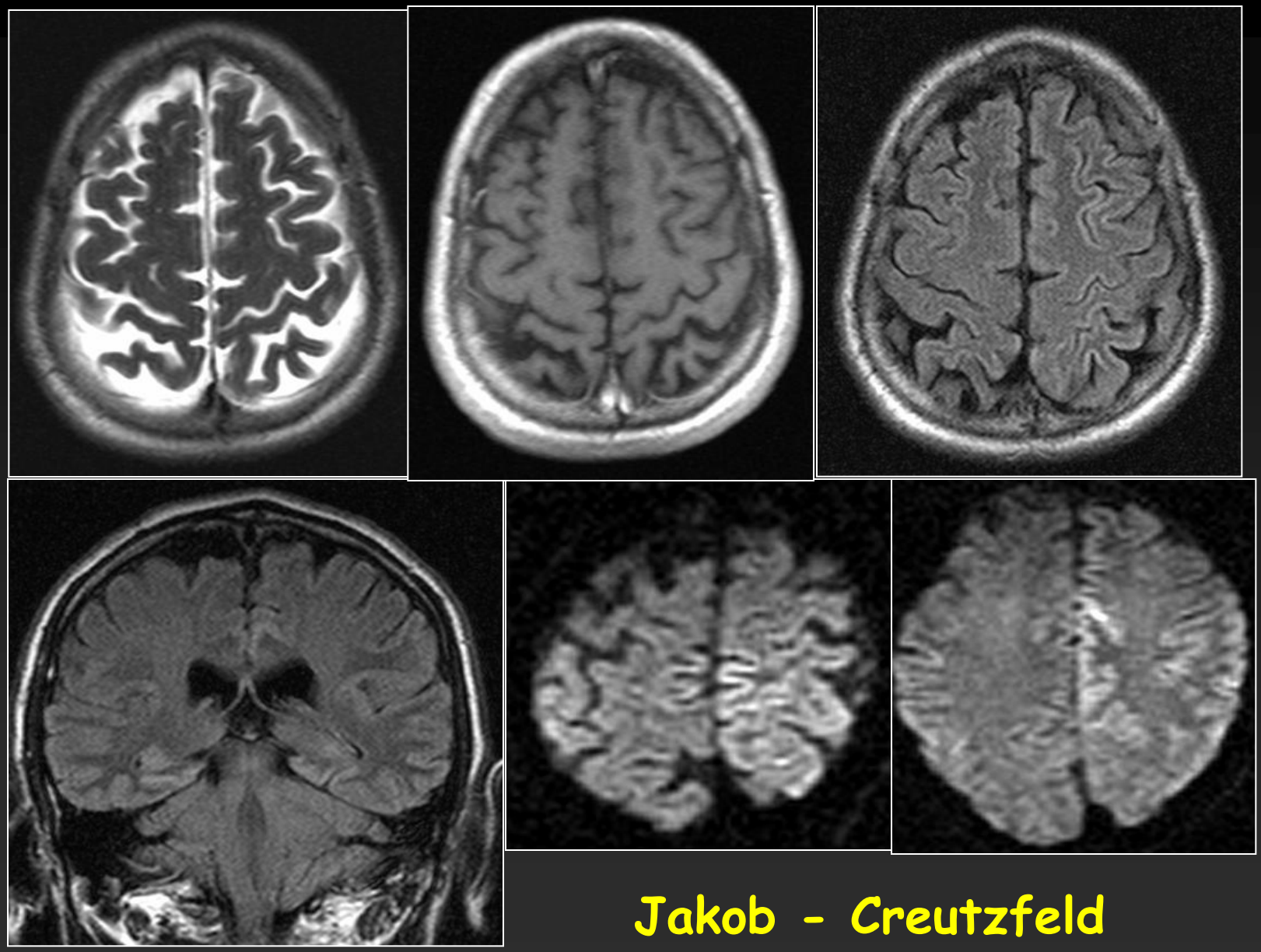

Jakob - Creutzfeld

Spinal Enfeksiyonlar

- Spondilit / Spondilodiskit
- Myelit / Radikülomyelit
- Leptomenenjit
- Araknoidit

Spinal Enfeksiyonlar

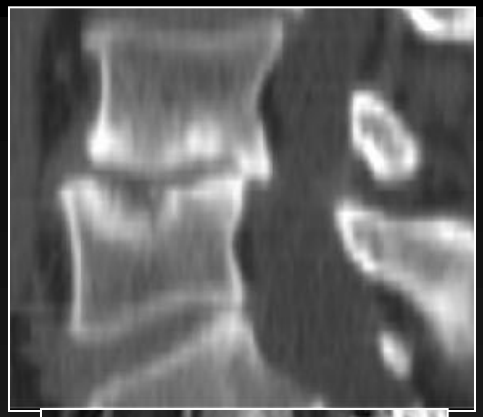

- Direkt grafiler yetersiz
- BT;
  - Erken evrede disk-plato tutuluşunu ya da epidural apseyi saptayamayabilir
  - Kitle ile ayırıcı tanıda yetersiz
  - Plato dej ile ayırıcı tanıda faydalı

Spondilodiskit

- Vertebra platolarında destrüksiyon
- Epidural, paravertebral abse / flegmon
- Disk aralığında sinyal artışı
- +C parlaklaşma:
  - Disk
  - Vertebral platolar
  - Abse / flegmon

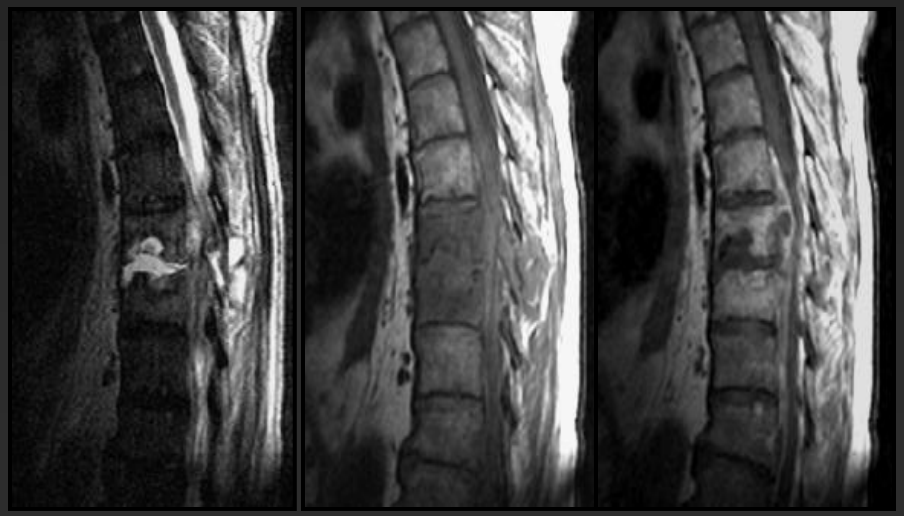

Akut spondilodiskit (Staph.)

T2

T1

CE T1

Spondilodiskit-menenjit-yumuşak doku enfeksiyonu

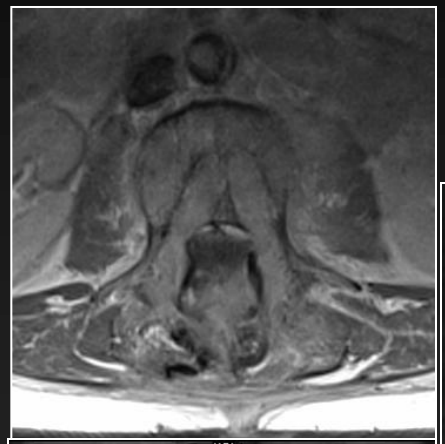

Spondilodiskit-menenjit-myelit-apse

Akut spondilodiskit (Tbc), paravertebral abse

T2 **T1** **CE T1**

Özetle

- BT; tanısal aşamada önemli; LP öncesi!
  - Tedavi sonrası komplikasyon takibi
    - Hidrosefali, ampiyem
- Seçilecek tanısal metot; MRG
  - Enfeksiyonun lokalizasyonu, tipi, yaygınlığı, varsa tipik özelliği, komplikasyonları ve tedavi etkinliği

Teşekkür ederim