OLGULARLA
TOKSİKOLOJİ PANELİ

ORGANİK FOSFOR ZEHİRLENMESİ

Dr. M. Nuri BOZDEMİR
Selçuk Ünv. Meram Tıp Fak. Acil Tıp AD

Sunum Planı

- Genel bilgiler
- Olgu örnekleri

Genel Bilgi

- Böcek öldürücü olarak tarım, ev, bahçe ve veteriner alanlarında
- Dünyada yıllık 3 000 000 maruziyet, 220 000 ölüm
- Türkiye 2008 yılında 77 988 zehirlenme vakasının 6503 (% 8,34) pestisit

Acil Başvuru Sıklığı

Zehirlenme türlerine göre :

Acil servise başvuran toplam hasta sayısı ; 115.868

14 yaş üzeri zehirlenme olguları ; 1818 (%1.57)

Akköse Ş. ve ark., The Turkish J. of Emergency Med.; 2003/1

Alım Şekli

- DERİ
- AĞIZDAN (KAZARA VEYA İNTİHAR AMAÇLI)
- SOLUNUM YOLU
- ENJEKSİYON

Organofosfat Tipleri

- Malation (Hektion, Malaton, Malathion)
- Paration (parathion 3
- Diazonin (Bazinon, Ba
- Metil paration (Folido
- Diklorvos (DDVP, Didifos, Nogos)

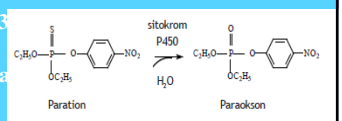

Şekil 1. Parationun karaciğərdə sitokrom P450 ənzim sistəmi tarafından paraoksona biyotransformasyon rəaksiyonu (20).

- **Kimyasal silah** (sarin,somon, tabu gibi sinir gazları)

Etki Mekanizması

- Organofosfat bileşikleri asetilkolin esteraza bağlanır
- Konformasyonel değişiklerle (aging) enzim geri dönüşümsüz deaktive edilir
- MSS sinapsları,
- Otonomik sinir sinapsları,
- Sinir kas kavşağında

} Aşırı asetilkolin

Asetil Kolin

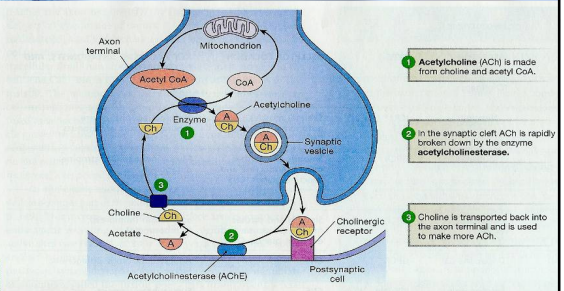

FIGURE 8-22 *Synthesis and recycling of acetylcholine at a synapse*

Silverthorn, D.U. (2007). Human physiology: An integrated approach 4th edition. San Francisco: Pearson, 274.

Asetil Kolin Esteraz

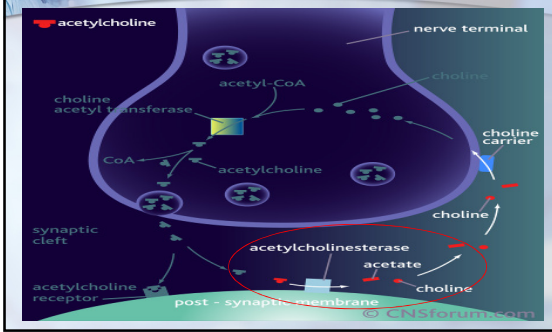

Normal Sinir Fonksiyonu

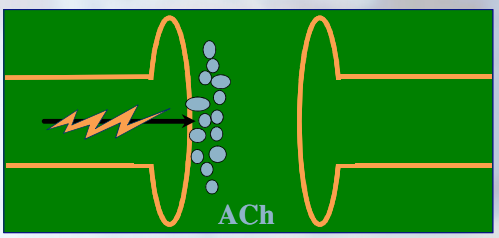

Normal Sinir Fonksiyonu

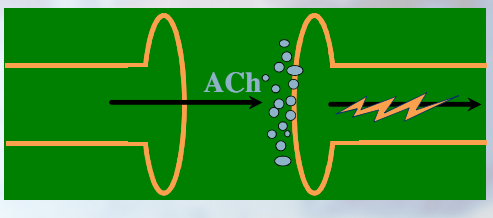

Normal Sinir Fonksiyonu

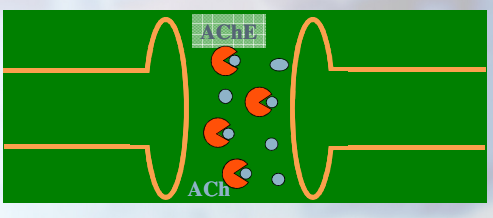

Organofosfat Etki

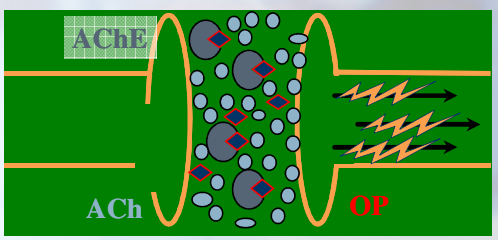

Klinik

- **Muskarinik**
  - Diyare
  - İdrar inkontinası
  - Miyozis
  - Bronkospazm
  - Bulantı
  - Lakrimasyon
  - Salivasyon
- **SSS**
  - SSS depresyonu, koma
  - Solunum merkezi disfonksiyonu
  - Nöbet
- **Nikotinik**
  - Paralizi
  - Terleme
  - Midriyazis
  - Hypertansiyon
  - Taşikardi
- **Kardiyovasküler**
  - Aritmiler
  - Hipertansiyon
  - Taşikardi
  - Doku iskemisi

Klinik

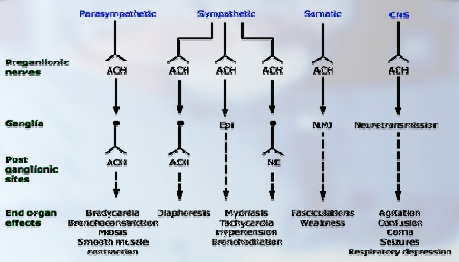

ACH: acetylcholine; Epi: epinephrine; NE: norepinephrine; NMJ: neuromuscular junction.

Klinik

- Akut Kolinerjik sendrom:
  - Santral
  - Periferal Muskarinik
  - Periferal Nikotinik

  } Solunum Yetmezliği

  + Ölüm
- Intermediate Sendrom
- Gecikmiş periferal nöropati
- Nörokognitif disrfonksiyon

Ara Sendrom

- Zehirlenen hastaların %10 - % 30'da
- Alım sonrası 24-96 saatlerde
- Nikotik reseptörlerde uzamış etki
- Belirgin özelliği bulbar, solunum ve proksimal kas güçsüzlüğü
- Hazırlıklı olunmazsa solunum yetmezliği, ölüm
- Genellikle 1-3 haftada tam düzelme

Gecikmiş Nörotoksisite

- Organofosfat tiplerine özgü
- Genellikle haftalar sonra
- Motor tutulum (simetrik motor polinöropati) alt ekstremitelerde flaks güçsüzlük, üst ekstremitelere ilerleme
- Duyusal bozukluk genellikle hafif
- Genellikle spontan düzelme, fakat kalıcı nörolojik hasar

Tanı

- Eritrosit asetilkolin esteraz aktivitesi:
  - Toksisite şiddetini ölçmede,
  - Antidot tedavi etkinliğini belirlemede değerli
- Plazma (psödo) kolin esteraz aktivitesi:
  - Çok kolay bakılabilir
  - Zehirlenmenin şiddeti ile korele değildir
  - Düzeyin % 25'in altına inmesi aşırı organofosfat emilimi için güçlü kanıt

Tedavi

- **Resusitasyon!**
  - A, B, C, D
  - Hafif zehirlenme vakaları bile hızlı solunum yetmezliğine gidebilir
- **Atropinizasyon**
  - Semptomatik hastalarda
- **Dekontaminasyon**
- **Diğer tedaviler ve oksimler**

Solunum Yetmezliği

- 376 orgonofosfat hastası değerlendirilmiş
  - 90 (%24) hastaya entübasyon gerekmiş
    - 52 (%58) hasta 2 saat içinde entübe edilmiş
    - 46 (51%) died
  - 29 (% 32) hasta hastaneye yatırıldıklarında iyiymiş >24 saat entübasyon

Eddleston M, Mohamed F, Davies JO, Eyer P, Worek F, Sheriff MH et al. Respiratory failure in acute organophosphorus pesticide self-poisoning. QJM. 2006;99(8):513-22.

Atropin

- Tanıdan şüphelenince hemen başlanmalı
- A,B,C'nin parçası ve eş zamanlı başlanmalı
- Yetişkinlerde 2-4 mg İV bolus 5-15 dakikada bir tekrar, atropinizasyon belirtileri çıkana kadar
- Çocuklarda 0,05 mg/kg başlangıç, takiben0,02-0,05 mg/kg

Atropin

- Yükleme
  - Double doz rejimi; her 5 dakikada bir 2 4 8 16 mg geometrik artış
- Devamında
  - Sürekli infüzyon< 3mg/hr
  - Saatte yükleme dozununun %10-20%'si
- Etkin doz
  - Akciğeri dinlemekle Whezing duyulmaması
  - Kalp hızı >80 vuru/dakika

Atropin

Endikasyon

- Bronkospazm ve bronşial sekresyon nedenli AC'e hava girişinin bozulması
- Hipotansiyon
- Bradikardi
- Aşırı terleme
- Miyozis

ATROPİN →

Sonlandırma

- Akciğerler temiz
- Sistolik KB >80mmHg
- Kalp hızı >100/dakika
- Kuru aksilla
- Pupil dilatasyonu

Atropin

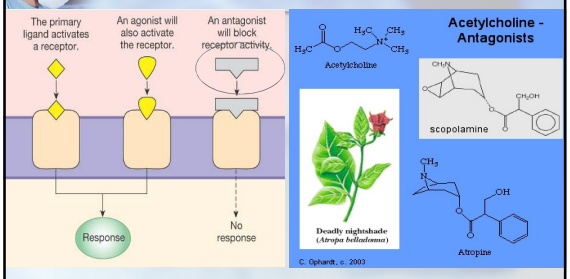

Silverthorn, D.U. (2007). Human physiology: An integrated approach 4th edition. San Francisco: Pearson, 274.

http://www.elmhurst.edu/~chm/vchembook/662cholinergic2.html

Atropin

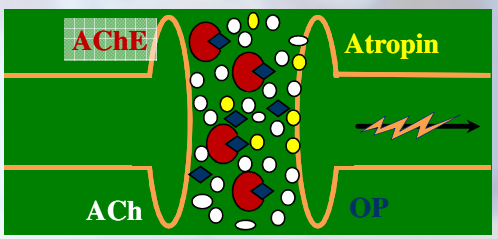

Dekontaminasyon

- Hayat kurtarıcı işlem değildir,resusitasyondan sonraya bırakılmalı
- Kontamine elbiseler çıkarılmalı
- Sabunlu su ile yıkama
- Bilinci açıksa kusturma ve gastrik lavaj
- Aktif kömür
- Sorbitol
- Sağlık personeli kontaminasyondan korunmalı

Oksimler

- Bazı durumlarda etkili değildir
  - Aging
  - Organofosfatlar arasında farklılık gösterir
- Etkili protokoller yerleşmemiştir
  - Farklı kullanım dozları vardır
    - Günlük 0– 24 gram arasında kullanılır

Araştırılan Diğer Tedaviler

- Magnezyum
  - Asetilkolin salınımını azaltır
  - Presinaptik kalsiyum kanal blokajı
  - İnsan çalışmaları sınırlı
- Klonidin
  - Presinaptik asetilkolin sentez ve salınımını azaltır
  - Santral sinir sistemi > periferik kolinerjik sinapslar
- Diazepam
  - Diazepam ratlarda solunum yetmezliğini primatlarda bilişsel defisitlerde azalma görülmüş
  - Solunum merkezinden gelen uyarıları azaltarak frenik sinir uyarılmasını azalttığı kabul edilir.

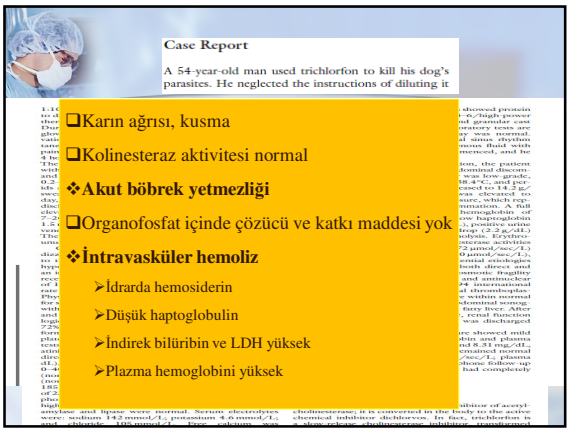

Case Report

A 54-year-old man used trichlorfon to kill his dog's parasites. He neglected the instructions of diluting it

- ❑Karın ağrısı, kusma
- ❑Kolinesteraz aktivitesi normal
- ❖**Akut böbrek yetmezliği**
- ❑Organofosfat içinde çözücü ve katkı maddesi yok
- ❖**İntravasküler hemoliz**
  - ➢İdrarda hemosiderin
  - ➢Düşük haptoglobulin
  - ➢İndirek bilüribin ve LDH yüksek
  - ➢Plazma hemoglobini yüksek

with a Glasgow Coma Scale score of 13. Her temperature was 37.5°C, pulse 135 beats per minute, blood pressure (BP) 164/95 mm Hg, and respiratory rate 21 breaths per

- ❖Tiroid krizi
- ❖Nikotinik reseptörler üzerinden
  - ➢Servikal sempatik nöronal nikotinik reseptörlerin uyarılması
  - ➢İnterfoliküler adrenerjik sinirlerden NE salınımı ve tiroid salınımı
- ❖Muskarinik reseptörler üzerinden
  - ➢Folikülden iyot organofikasyonunu uyarır

per minute, temperature 42°C, and pulse oximeter showed oxygen saturation of 76% (FiO_2, less than 50%). She thus

- ❑Asetil kolin nedenli pankreatik asiner hücrelerin aşırı uyarılması
- ❑Subklinik olgnlara dikkat edilmeli
- ❑Düşünülmesse tanı zorlaşır

Figure 1 Massive enlargement of the pancreas with heterogenous hypodens areas at corpus and unorganised fluid extending from the anterior of the pancreas corpus to the posterior wall of the stomach at abdominal CT.

2. Case report

A 22-year-old ... pain, vomiting ... reported to ... had attempted ... 4 ml of an ... w/w fenthion ... ago. A diagnosis ... ment with atropine ... tion deteriorated ... respiratory distress ... tory support ... Serum cholinesterase ... 4950 IU/L ... tion of pralidoxime ... 1 g every 8 h ... of admission, ... of the affected arm, extending up to the shoulder. The radial pulse was found to be absent. An emergency fasciotomy of the arm restored the radial pulse (Fig. 1). Gradually there was complete resolution of her cholinergic symptoms.

Fig. 1. Photograph of the affected arm showing fasciotomy incisions.

Atropine was tapered off and she was weaned from artificial ventilation and required mechanical ventilatory support. Finally, she was successfully weaned from ventilator on day 31 and was shifted to the ward on 35th day of her admission to ICU.

- ❑Fention uzun etkili OP
- ❑Çift fosforlu ve yağda çözünürlülüğü iyi
- ❑İntermediate sendromu çok uzun sürmüş
- ❑Enjeksiyonlarda atravmatik kompartman sendrom!

Genel Tıp Derg 2006;16(1)

- ❖Organofosfat nedenli koroner vasospazm
- ❖Riskli hastalarda EKG ve enzim takibi

Myoglobin (ng/mL)	203	154

enzimleri n... nesi gelişti ve kardiyak enzimleri yüksek saptandı. Bu bulgularla hastada OP zehirlenmesine bağlı ST yükselmeli AMI düşünüldü. Zehirlenme ve AMI tedavisi sonrası yoğun bakımda ve serviste klinik bulguları tamamen düzelen hasta komplikasyonsuz taburcu edildi. **Sonuç:** OP zehirlenmesi ile başvuran hastalarda zehirlenmeye sekonder ortaya çıkan akut AMI gözardı edilmemelidir. Böyle bir şüphe durumunda EKG ve kardiyak enzim izlemi önerilir.

Original Research Article

Skin Pharmacol Appl Skin Physiol 2002;15:195–199 Received: Feb. 2, 2000 Accepted: Sept. 27, 2001

Systemic Organophosphate Poisoning following the Percutaneous Injection of Insecticide

Case Report

Necmiye Hadimioglu Levent Dosemeci Gulbin Arici Atilla Ramazanoglu

Medical College of Akdeniz University, Antalya, Turkey

Key Words: Organophosphate - Poisoning - Injection, percutaneous - Insecticides - Suicide

Abstract: Organophosphates are the most common group of chemicals in the southern part of Turkey. Although organophosphate poisoning (OPP) may occur due to skin exposure or inhalation, severe poisoning is usually the result of ingestion to attempt suicide. Despite the fact that there have been a lot of experimental studies using intravenous or percutaneous injection of organophosphates, reports of human poisoning due to percutaneous injection are rare. The systemic signs of OPP have not been described in these reported patients. We report 2 cases having systemic signs of OPP due to percutaneous injection. In our first case, we noticed a 17-day muscle weakness and a 12-day muscarinic syndrome, which required prolonged atropinization. In the second patient, atropine infusion had to be continued for 2 days. Both cases also had severe swelling of the affected limb and wound infection. In conclusion, in cases of percutaneous injection of organophosphates systemic toxicity may develop in addition to local findings such as necrosis and abscesses. Close observation for evidence of systemic involvement is required, and the patient should be carefully monitored for secondary abscess formation and any delayed impairment of neurologic function.

Copyright © 2002 S. Karger AG, Basel

Introduction

Organophosphate poisoning (OPP) represents a serious problem because of the extensive use of these chemical compounds in agri-

Case Reports

Case 1

A 15-year-old girl was admitted from another health centre, having injected about 5 ml of organophosphate (fenthion) into the antecubital area, in a suicide attempt a few hours previously. She had been treated there with 2.5 mg i.v. atropine and was referred to Akdeniz University Hospital. After 3 h from injection, the patient arrived at our hospital in a conscious state with a blood pressure of 110/70 mm Hg, a pulse rate of 134 beats/min and temperature of 36.5°C. The diagnosis of OPP had been confirmed clinically by the presence of pupillary constriction, muscular fasciculation, vomiting, salivation and abdominal pain. There was no respiratory distress, so intubation was not required. Plasma cholinesterase activity was 0.2 U/ml (normal range 4.7–10.5 U/ml). The patient had been treated initially with pralidoxime chloride (25 mg/kg) and intravenous atropine infusion (0.75 mg/h). The dose of atropine was titrated according to the patient's response such as salivation, size of pupils, abdominal pain and heart rate, and the atropine infusion had to be administered until the end of the 12th day. The total dose of infused atropine was 200 mg. Pralidoxime was repeated every 6–12 h for 2 days. On account of the wound infection at the injection site (Fig. 1), we used ampicillin + sulbactam (3 g/day) for 7 days. By the 12th day of exposure, all symptoms had subsided except for the generalized muscle weakness, which persisted until the 17th day. Owing to the prolonged muscle weakness, the patient could be discharged only on the 17th day. Two months later, there was no problem at the injection site, and the plasma cholinesterase level was 5.4 U/mL. Because of the poisoning, which resulted from a suicide attempt, psychiatric support for the management of suicidal behaviour was required.

Case 2

A 22-year-old man was admitted from another health centre following poisoning by subcutaneous injection of organophosphate to commit suicide. A total of 4 ml of organophosphate (dichlorvos) had been injected into the medial region of the left forearm at four different sites. Two milligrams of intravenous atropine had been given to the patient prior to the admission to our ICU. When the patient arrived at our hospital after 4 h from the injection, he had systemic symptoms, such as vomiting, abdominal pain, incontinence of faeces, excessive sweating, generalized muscle weakness and miotic pupils. There was no respiratory distress, so intubation was not required. The heart rate was 52 beats/min, with a blood pressure of 100/70 mm Hg. The plasma cholinesterase level was 0.72 U/ml (normal range 4.7–10.5 U/ml). The patient had been treated initially with pralidoxime chloride (25 mg/kg) and intravenous atropine infusion (2 mg/h). The atropine dosage was titrated to 0.5–3.0 mg/h according to the patient's response, and at the end of 48 h the atropine infusion was stopped. In the first 2 days, a total dose of 100 mg atropine was given. Pralidoxime was repeated 12 h after admission. Owing to the wound infection of the injection site, we began to use ampicillin + sulbactam (3.5 g/day) until the 7th day. Eight hours after injection, all symptoms improved except for the generalized muscle weakness, which persisted until the 4th day. Two days later, there were black crusts over the wounds and induration around them

conclusion

Intravenous or percutaneous injection of organophosphates could potentially represent a life- or limb-threatening injury. The amount and determination of the systemic involvement must be rapidly assessed. Systemic signs of OPP are important, but major morbidity occurs locally in patients with injection of organophosphate [9]. Local complications at the site of the injection, like necrosis and abscesses, are also expected findings. Our

---

HET

perimental Toxicology
28(8) 521–524
© The Author(s) 2009
ermission: http://www.
ournals/Permission.nav
77/0963271093480B2
het.sagepub.com
SAGE

❖Şüpheli ölümler mutlaka adli mercilere bildirilmeli

❖Dikkatli fizik bakıda enjeksiyon izleri

Gökhan Batuk and Hülya Işler Batuk

Abstract

We present the first ever case of homicidal poisoning due to injection of methidathion, an organophosphate insecticide. *Case*: A 4-month-old baby presented to the emergency department with chief complaints of unconsciousness and irregular respiration. A bitter odour and an injection site with a greenish blue colouration and two bullaous lesions were noticed by the emergency department physicians. Postmortem examinations revealed a wide shiny blue colouration of the antecubital region with oedematous muscular fascia and focal liquefaction necrosis. Blood and tissue levels were positive for methidathion. Our case report emphasizes the necessity of a detailed crime scene investigation and postmortem examination for the possibility of homicide in such cases. Although injection sites may be the expected results of medical treatment, dermal lesions also may be associated with injections of toxic substances.

Case report

A 28-year-old unmarried female garment factory employee was admitted to casualty with severe diarrhea and vomiting of about 6 hours duration. The doctor in the factory health center had made a diagnosis of food poisoning and prescribed oral rehydration therapy. As the diarrhea and vomiting worsened, she was referred to a hospital. On admission, she was conscious and moderately dehydrated.

She had cold extremities, her pulse rate was 90/min and blood pressure was 90/60 mmHg. Respirator neurological, and abdominal examinations wer normal.

Her diarrhe morning and medical and microscopy an and serum cr intravenous f vomiting.

Later that day, she developed fasciculations in lim and abdominal muscles. This, together with he uncooperative behavior, led to suspicion of O poisoning which is common in this country. Clos monitoring of the patient was carried out, and 1 hours after admission, she developed pin-poi pupils and a bradycardia (pulse rate 56/min). O confronting the patient with the available clinic evidence, she admitted to injecting her right calf wit about 5 ml of "Baytex" (Bayer) (an emulsifiabl concentrate containing 82.6% of the OP fenthion [O,O-dimethyl-O-(3-methyl-4-methylthiophenyl) phosphorothioate; used for control of mosquito larva LD_{50} mg/kg rats: 586).[5] An area of mild erythem which had not been noticed at admission, was foun at the site of the injection. Serum cholinesterase lev was 220 u/l (normal range 5300–12,900 u/l). Intra venous atropine and pralidoxime therapy was started The incriminating syringe and poison bottle wer later recovered from her room at home.

It was difficult to titrate the dose of atropine as sh had frequent swings from cholinergic excess t

378

atropine poisoning. On the fourth day of admission, she developed respiratory insufficiency with low tidal

he Inter-
positive
ge doses
days. A

psychiatric assessment after recovery suggested severe distress and reactive depression over a dispute with her fiancé in addition to socioeconomic problems. Prior to joining the factory, she had worked as a trainee nursing assistant at a private hospital for 1 month where she had observed injections being administered. She had got the idea of injecting herself with the poison rather than ingesting it after reading the newspaper report of a homicide involving injection of a weedicide.

➢Besin zehirlenmesi tanısı koyarken dikkat!

Case report

A 19-year-old male complaining of nausea and abdominal pain for 1 h was admitted to the emergency department Diskapi Yildirim Beyazit Training and Education Hospital, Turkey. He gave a history of injection of nearly 1 ml (550 mg–9.48 mg/kg) of an insecticide {2,2-dichlorovinyl dimethyl phosphate [dichlorvos, Festline-DDVP (Doğal, Istanbul, Turkey)], concentrated emulsion = 550 g/l} injected intravenously through cubital vein 2 h earlier. He had no history of chronic medical disease or long-standing medication. On admission, physical examination, unconscious and the GCS was 7 (eye: 1, motor: 4, verbal: 2). His blood pressure was 85/60 mmHg and heart rate was 47 beats/min. Three tonic clonic seizures, each less than 5 min duration were seen in the first 5 h of admission. During seizures, intravenous doses of diazepam (5 mg) were applied. At the seventh hour of admission the GCS was 15; his blood pressure and heart rate were normalized.

European Journal

:011, Vol 18 No 2

Intravenous
injection and

:ichlorvos)
:t of toxin

Fatih E
Departi
Diskapi

Corresp
Diskapi
06110
Tel: + 9
e-mail:

Receiv

Intro
Orga
most important
many developing
to insecticides v
inhalational, and
intravenous expo
a case of a pa

intravenously for 48 h. After 2 h of admission he became unconscious and the GCS was 7 (eye: 1, motor: 4, verbal: 2). His blood pressure was 85/60 mmHg and heart rate was 47 beats/min. Three tonic clonic seizures, each less than 5 min duration were seen in the first 5 h of admission. During seizures, intravenous doses of diaze-

Turkey, as in
de of exposure
gastrointestinal,
er few cases of
crein, we report
intravenously,
notable for early and late manifestations of OPC exposure.

European Journal of Emergency Medicine 2008, Vol 15 No 4

Acute organophosphate poisoning mimicking opioid intoxication

Ahmet Baydin*, Dursun Aygun*, Macit Aydin*, Hzr Ufuk Akdemir* and Fatma Ulger**, Departments of *Emergency Medicine and **Anaesthesiology, Faculty of Medicine, Ondokuz Mayis University, Samsun, Turkey

Case report

An 18-year-old female patient was admitted to the Emergency Department (ED) with respiratory failure. In the medical background of the patient, there was no history of significant illness. Her initial vital signs were as follows: blood pressure, 80/60 mmHg; pulse rate, 90 beats/min; resp temperature, <3 ous (Glasgow Co and had miotic p cholinergic activity, such as fasciculation, emesis, or brady-cardia, was not found. Other systemic examinations were normal.

In the laboratory findings, white blood cell count was 44.9 ul (3.58–11.07) and glucose was 323 mg/dl (70–110), whereas other findings were within normal limits. Arterial blood gas examination revealed respiratory acidosis with pH 7.0, P_{CO_2} 106 mm/Hg, P_{O_2} 138 mmHg, and HCO_3 24.2 mmol/l.

As soon as the patient was admitted to the ED, she was entubated and connected to a mechanical ventilator. Intravenous saline (0.9%) and activated charcoal (1 g/kg) through nasogastric tube were also administered. The patient was observed closely at our emergency critical care unit. She was extubated and oxygen was delivered by

on became normal again,
anical ventilator. As she
rmia, and miosis, but no
ent, her clinical picture
oning. For this reason,

naloxone was given (initially 0.4 mg intravenously, repeated doses of 2 mg every 3 min up to 10 mg) to relieve the effects of the opioid. The patient did not respond to the naloxone therapy, however, and her respiratory depression and mental status remained the same. So atropine and pralidoxime were administered for a probable acute OPP and the patient was directed to the intensive care unit. A low pseudocholinesterase level was measured on the fifth day. On the 15th day of admittance, the patient made a complete recovery and was discharged.

➢Ayırıcı tanıda toksidrom!

Acta Med. Okayama, 2001
Vol. 55, No. 2, pp. 129-132

Acta Medica Okayama

Case Report

Severe Fenitrothion Poisoning Complicated by Rhabdomyolysis in Psychiatric Patient

Koujiro Futagami**, Naofumi Hirano*, Emiko Iimori*, Kenichi Motomura*, Michio Ide*, Yasuhumi Kataoka*, Hiroaki Araki*, Yutaka Gomita*, and Ryozo Oishi*

Non-traumatic rhabdomyolysis
reported. We report here in a
A 43-year-old woman ingested

Case Report

A 43-year-old woman was admitted to the Emergency Ward of St. Mary's Hospital following suicidal ingestion of an approximately 100 ml fenitrothion emulsion (50%). She had been treated with various medications including bromperidol, propericiazine, trihexyphenidyl HCl, diazepam, and nitrazepam for a medical history of schizophrenia. The patient's blood pressure was 110/70 mmHg, and her pulse was 126 beats/min. On arrival, she exhibited vomiting, loss of sensation in the arms and legs, and muscle fasciculation (clonic seizures) requiring intravenous diazepam. Both eyes were deviated upwards. Laboratory data included: hemoglobin 14.6 g/dL, white blood cells 19,500/mm³, platelet 250,000/mm³, GOT 46 IU/L, GPT 19 IU/L, blood glucose 265 mg/dL, blood urea nitrogen (BUN) 14.2 mg/dL, serum creatinine 0.66 mg/dL, potassium 5.87 mEq/L (normal: 3.5–4.8 mEq/L), calcium 8.8 mg/dL, sodium 145.1 mEq/L, chloride 103.1 mEq/L, serum creatine phosphokinase (CPK) 3191 IU/L (normal: 14–158 IU/L), lactate dehydrogenase (LDH) 1,315 IU/L (normal: 200–400 IU/L), amylase 482 IU/L (normal: 105–440 IU/L) PaO_2 125.0 mmHg, $PaCO_2$ 39.4 mmHg, pH 6.91, HCO_3 7.5 and base excess −26.5 mmol/L. The erythrocyte and plasma cholinesterase activities (EChE and PChE) were 6,541 IU/L (normal: 10,000–14,000 IU/L) and 656 IU/L (normal: 1,500–3,900 IU/L), respectively, and the plasma concentration of fenitrothion was 18.8 μg/ml. Gastrointestinal lavage followed by activated charcoal treatment was performed immediately. Ventilation was immediately supported via a nasal endotracheal tube due to inadequate respiration. Sodium bicarbonate was intravenously administered to correct the acidosis. PAM (2.0 g) was intravenously infused, but atropine sulfate was not given because her pupils were almost normal and no excessive salivation was observed.

On day 3 (52 h after ingestion), her CPK peaked at 47,762 IU/L (6.9% of the MB isoenzyme). GOT and LDH were elevated similarly to CPK and peaked at 238 IU/L and 2,760 IU/L, respectively (Fig. 1). Serum myoglobin and aldolase on day 4 were 5,500 ng/ml (normal under 35 ng/ml) and 363.0 IU/L (normal: 1.7–5.7 IU/L/37 °C), respectively. These results suggested complications of rhabdomyolysis. The patient was therefore treated with sodium bicarbonate and hydration to protect her kidney function from acidosis and precipitation of myoglobin in the tubules.

The plasma levels of fenitrothion decreased gradually from a high initial level on admission, but it continued to be detected until 25 days after ingestion (Fig. 2). Since excessive miosis, salivation, and fasciculation developed on day 5, atropine sulfate was administered to keep the pupillary enlargement within a mild range. The intravenous infusion of PAM at 0.25 g/h for 6 days was restarted 10 days after administration was initially stopped because of persisting severe cholinergic symptoms.

Paralleling the recovery of EChE and PChE activities, the clinical findings of organophosphate intoxication gradually disappeared. Serum creatinine maintained a normal level during the therapeutic period. A mild BUN elevation of 28.4 mg/dL (normal 10–20 mg/dL) was recognized from day 6. CPK became temporarily elevated again on day 18 following a lack of muscle fasciculation control, but the patient exhibited an almost complete recovery by day 38.

The Journal of Emergency Medicine, Vol. 29, No. 2, pp. 217–219, 2005
Copyright © 2005 Elsevier Inc.
Printed in the USA. All rights reserved
0736-4679/05 $–see front matter

☐ A BOY WITH ORGANOPHOSPHATE POISONING MIMICKING A FOREIGN BODY

❖Çocuklarda yabancı cisim aspirasyonunu taklit edebilir

❖Dikkatli hikaye ve fizik muayene

❖Genel anestezide suksinil kolin!

CASE REPORT

Neonatal cholinergic syndrome – organophosphate poisoning or herbal medicine intoxication?

❑Tanı için yüksek şüphe

❑Zehirlenme semptomlarının iyi bilinmesi

❑Herbal ilaçlara dikkat

➢Aspirasyon!

Case report

❖Serebellar ataksi

➢Serebellumda purkinje ve granül hücrelerin etkilenmesi

➢Postmortem serebellum kolinesteraz düzeylerinde % 60-85 azalma

❖ Distoni, istirahat tremoru, korea gibi ekstrapiramidal etkiler

FROM THE CENTERS FOR DISEASE CONTROL AND PREVENTION

MMWR WEEKLY REPORT

❑Acil personeli yüksek sekonder kontaminasyon riski taşır

❑Uygun giysi, eldiven ve maske kullanmalı

➢ÖNCE GÜVENLİK!

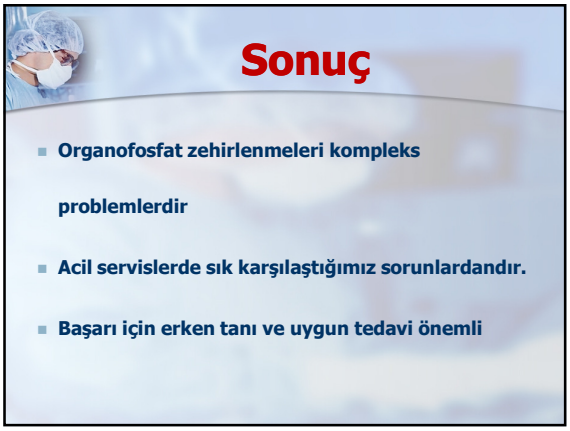
Sonuç
Organofosfat zehirlenmeleri kompleks problemlerdir
Acil servislerde sık karşılaştığımız sorunlardandır.
Başarı için erken tanı ve uygun tedavi önemli

SABRINIZ İÇİN TEŞEKKÜRLER