# AKUT KORONER SENDROM TANISINDA ACİL EKO

DOÇ. DR. SADIK GİRİŞGİN
N.E.Ü. MERAM TIP FAKÜLTESİ
ACİL TIP AD

# Akut Koroner Sendrom

- **AMİ veya UAP olduğunu düşündüren klinik bulgu ve semptomları kapsar.**

BU SENDROM;

- **STEMI,**
- **NSTEMI,**
- **UAP** kapsar.

# Problar

2.5-3.5 MHz frekanslı

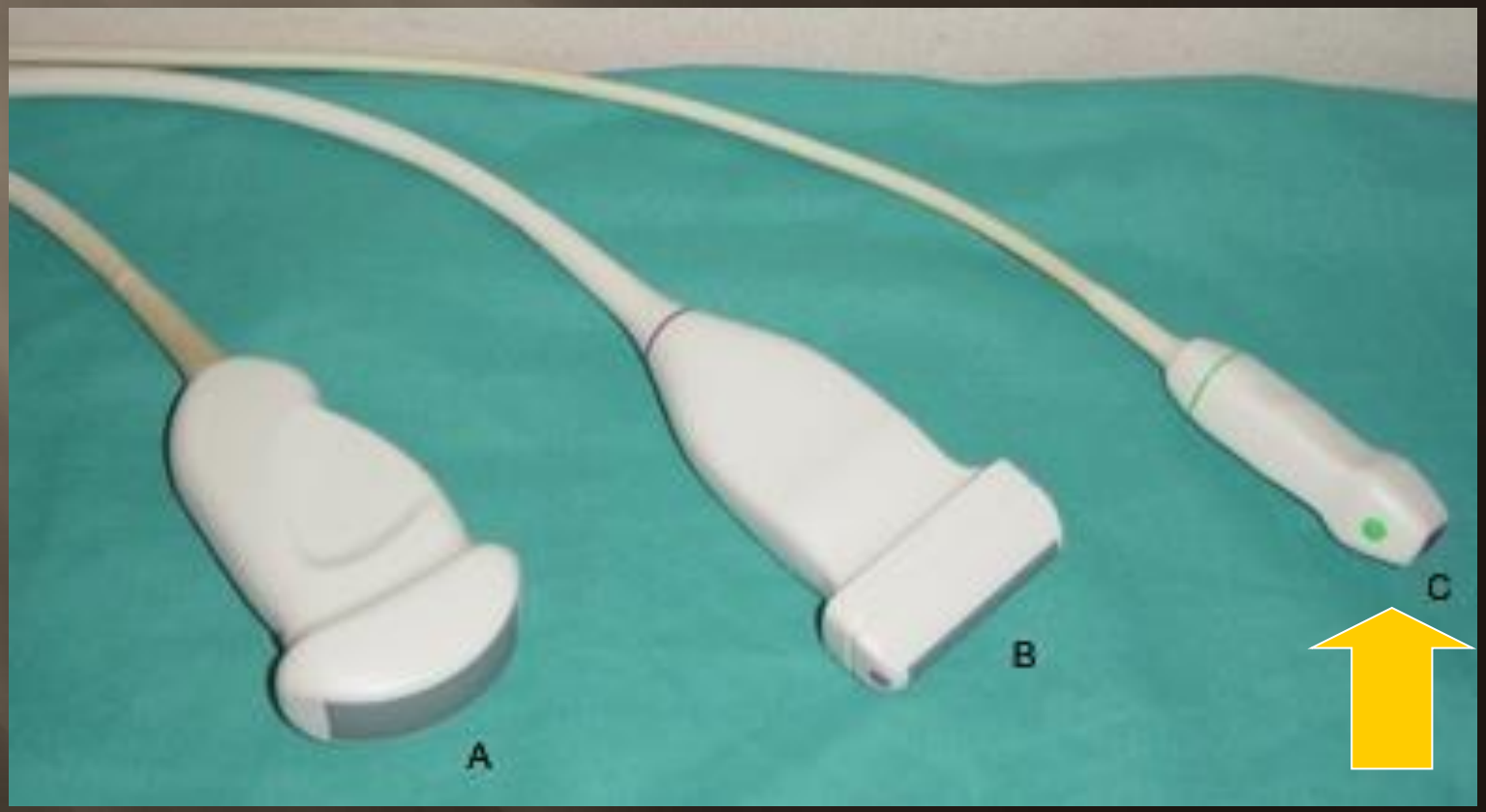

# History

- 1953: Hertz & Edler
- 1950s – 1960s: M mode
- Early 1960s: cranial US (A mode)
- Late 1960s: Doppler
- Early 1970s: 2D static (B mode)
- Late 1970s: Real-time 2D and color
- Early 1980s: TEE
- Late 80s - 90s: Explosion in USS technology
- 1968: First echo meeting
- 1975: ASE

# Hangi durumda EKO yapılır?

| | |
|---|---|
| **Kalpte duyulan üfürümlerin değerlendirilmesi** | • Kalbinde üfürüm duyulan ve kalp-akciğer semptomları olan hastalar<br>• Kalbinde üfürüm duyulan, klinik özellikleri yapısal kalp hastalığını düşündüren hastalar |
| **Kapak Hastalıkları** | • Kapak morfolojisi ve etyoloji<br>• Yetersizlik ve / veya darlık derecesi<br>• Ventrikül boyut ve fonksiyonlarının değerlendirilmesi |
| **İnfektif Endokardit** | • Vejetasyon, abse, fistül, kapak perforasyonu<br>• Ventrikül boyut ve fonksiyonlarının değerlendirilmesi |
| **Koroner Arter Hastalığı ve Akut Miyokard İnfarktüsü** | • Duvar hareket bozukluğu<br>• Sol ventrikül fonksiyonları<br>• Sağ ventrikül fonksiyonları<br>• İskemik komplikasyonların değerlendirilmesi (Sol ventrikül anevrizması, mitral yetersizliği, ventriküler septal defekt, perikard sıvısı) |
| **Konjestif Kalp Yetersizliği** | • Sol ve sağ ventrikül boyutları ve sistolik fonksiyonları<br>• Duvar hareket bozuklukları<br>• Kapak patolojileri<br>• İskemik komplikasyonların değerlendirilmesi |
| **Perikard Hastalıkları ve Kalp Tamponadı** | • Perikard sıvısı, perikardda kalınlaşma ve / veya kalsifikasyon<br>• Sağ ventrikül boyut ve fonksiyonları<br>• Mitral, triküspid, pulmoner venöz, hepatik ven akımlarında solunum ile<br>• değişiklikler, vena cava inferior çapı ve solunum ile değişiklikleri<br>• Atriyum ve ventriküllerde kollapsın değerlendirilmesi |
| **Çıkan Aort Patolojileri** | • Anevrizma, ateroma, disseksiyon, intramural hematom<br>• Aort kapak patolojisinin değerlendirilmesi |
| **Pulmoner Hipertansiyon** | • Sağ ventrikül sistolik basıncı<br>• Sağ ve sol ventrikül fonksiyonları<br>• Triküspid, pulmoner ve mitral kapak patolojilerinin değerlendirilmesi |
| **Sistemik Hipertansiyon** | • Sol ventrikül sistolik ve diyastolik fonksiyonları<br>• Sol ventrikül duvar kalınlığı<br>• Sekonder nedenlerin değerlendirilmesi |
| **Embolik Hastalıklar** | • Sol atriyum ve sol ventrikül trombüsü<br>• Sol ventrikül boyut ve fonksiyonları<br>• Mitral kapak patolojisi, aortta ateroma, interatriyal şant değerlendirilmesi |
| **Aritmiler** | • Sol atriyum ve sol ventrikül trombüsü<br>• Atriyum ve ventriküllerin boyutları ve fonksiyonları<br>• Mitral kapak patolojilerinin değerlendirilmesi |
| **Senkop** | • Sol ventrikül çıkış yolu obstrüksiyonu<br>• Aort ve mitral kapak patolojileri<br>• Sol ventrikül fonksiyonları<br>• Konjenital lezyonların değerlendirilmesi |
| **Kalp Travmaları** | • Çıkan aort disseksiyonu, anevrizması<br>• Kalp tamponadının değerlendirilmesi |
| **Konjenital Kalp Hastalıkları** | • Konjenital anomaliler ve şantlar<br>• Pulmoner debinin, sistemik debiye oranının değerlendirilmesi |
| **Şokta ve Ağır Klinik Tabloda olan hastalar** | • Sol ventrikül fonksiyonları ve kapak patolojileri<br>• Perikard sıvısı ve tamponad, sağ-sol şant, hacimlerin değerlendirilmesi |

# Acilde Hangi durumda kardiyak USG yapılır?

- Toraks-karın travması (FAST)
- Kardiyak arrest /NEA
- Nedeni bilinmeyen hipotansiyon / dispne

  (PE, Hipovolemi, Miyokard iskemisi, Efüzyon/tamponad)
- Akut kardiyak iskemi
- Perikardiyosentez
- Eksternal pacer (yakalanma oldu mu?)
- Transvenöz pacer takılması

# AKS'da EKO aşağıda ki durumlarda kullanılır

- Tanının doğrulanması ve ayırıcı tanıların dışlanmasında
- Komplikasyonların tespitinde
- Tedavi stratejisi (erken revaskülarizasyon, değerlendirme), IABP
- Risk yönetimi

# Koroner Arter Hastalığı ve Akut Miyokard İnfarktüsü

- Duvar hareket bozukluğu
- Sol ventrikül fonksiyonları
- Sağ ventrikül fonksiyonları
- İskemik komplikasyonların değerlendirilmesi (Sol ventrikül anevrizması, mitral yetersizliği, ventriküler septal defekt, perikard sıvısı)

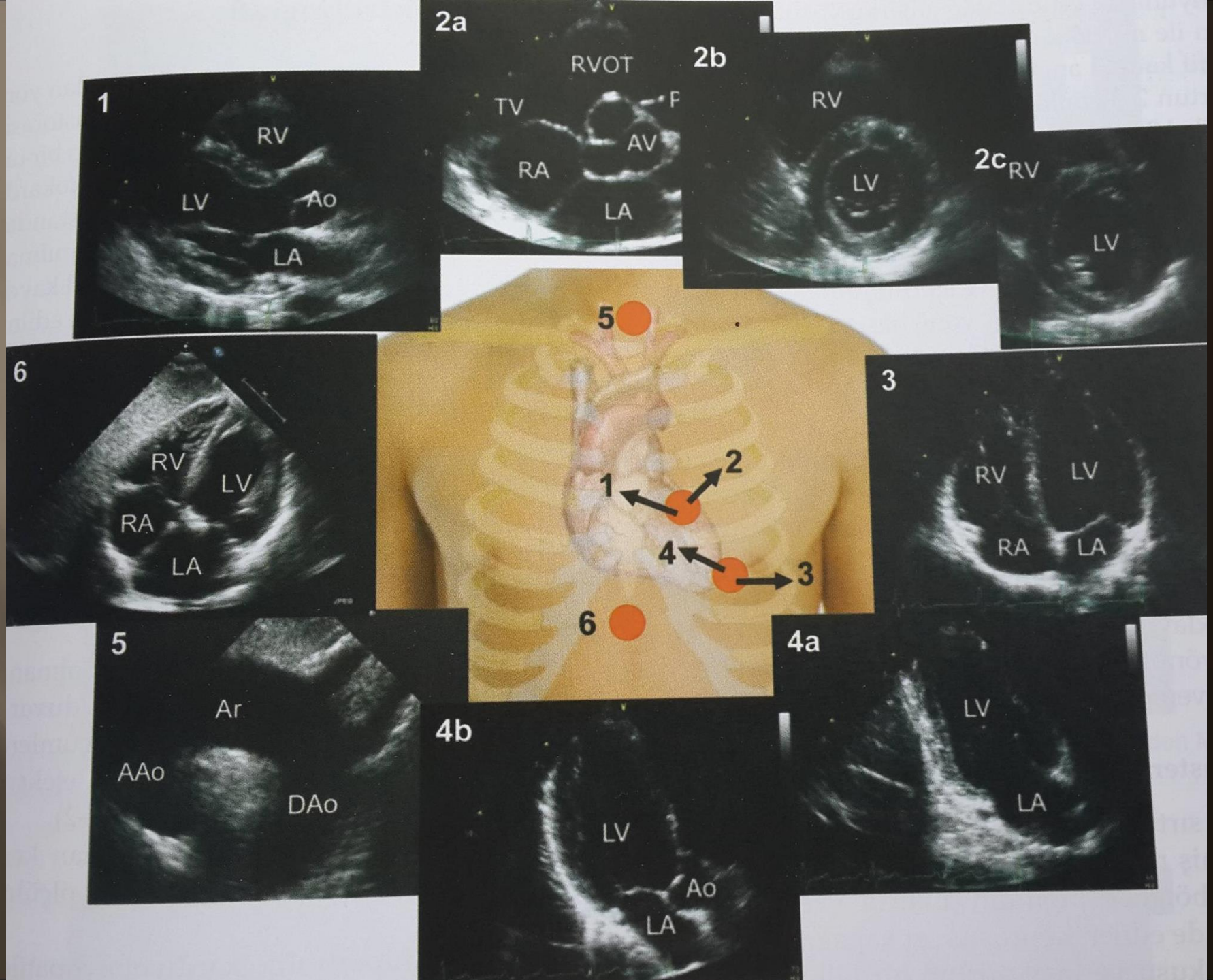
1
RV
LV
Ao
LA
2a
RVOT
TV
AV
RA
LA
2b
RV
LV
2c
RV
LV
5
1
2
4
3
6
6
RV
LV
RA
LA
3
RV
LV
RA
LA
5
Ar
AAo
DAo
4b
LV
Ao
LA
4a
LV
LA

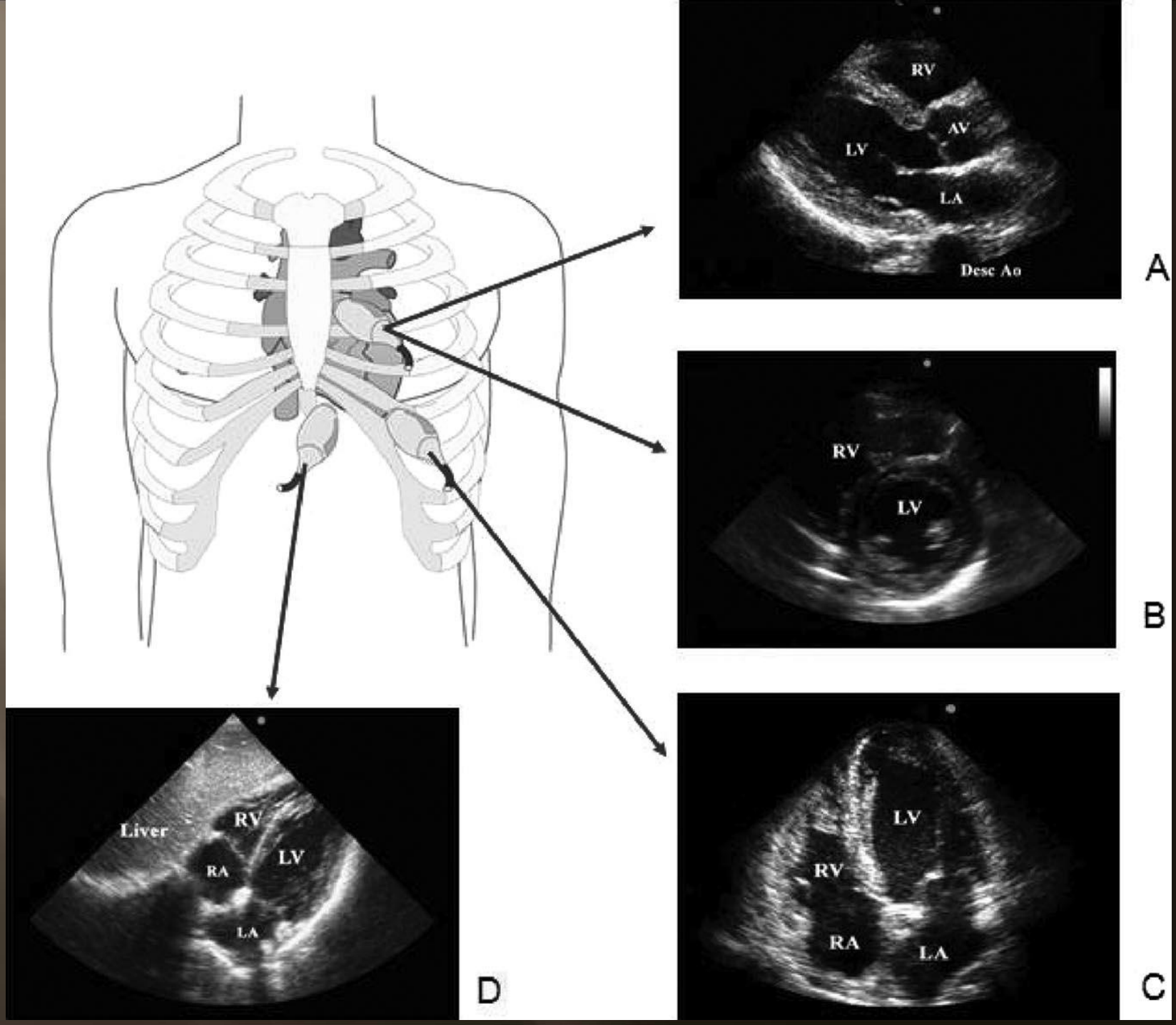
RV
AV
LV
LA
Desc Ao
A
RV
LV
B
LV
RV
RA
LA
C
Liver
RV
LV
RA
LA
D

# Duvar hareketleri

- Normal
- Hipokinetik
- Akinetik
- Diskinetik: kasılma olmuyor veya sistol esnasında dışarı hareket ediyor

- Hiperkinetik

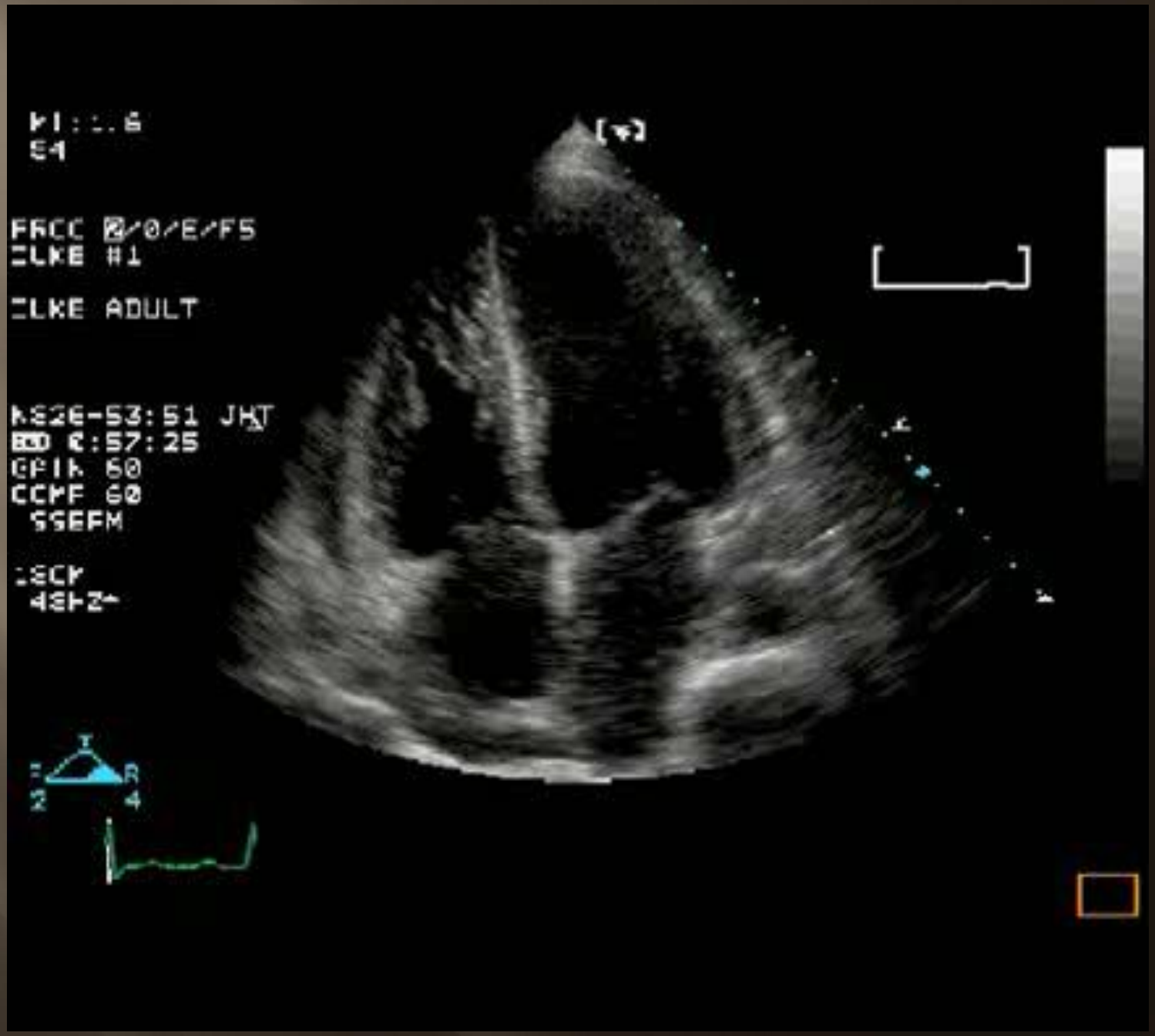
ADULT

# Parasternal Yönler

- Çok yararlı, özellikle sol ventrikül için
- Odacık boyutları
- Lokalize efüzyonlar
- Efüzyon

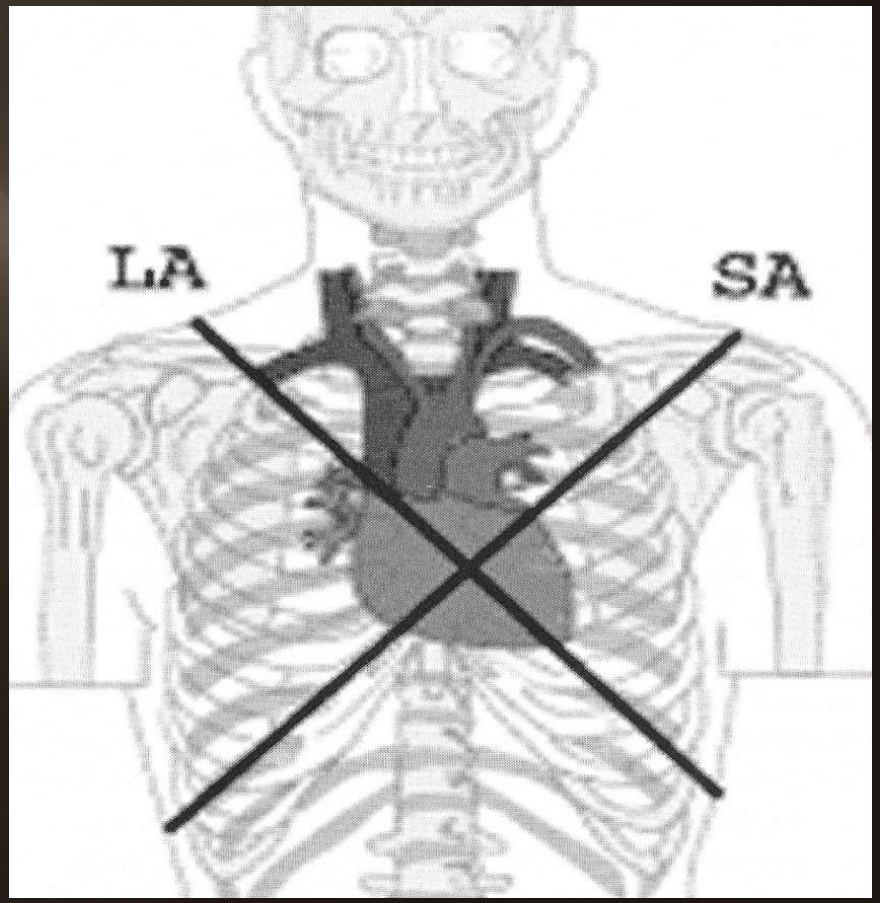

# Parasternal Uzun Aks

- Sternum yanında
- 3. veya 4. sol interkostal aralıkta
- Çıkıntı sağ omuza doğru

# Parasternal - Uzun aks

LV
Aort ve Mitral kapak
Aort kökü
LA

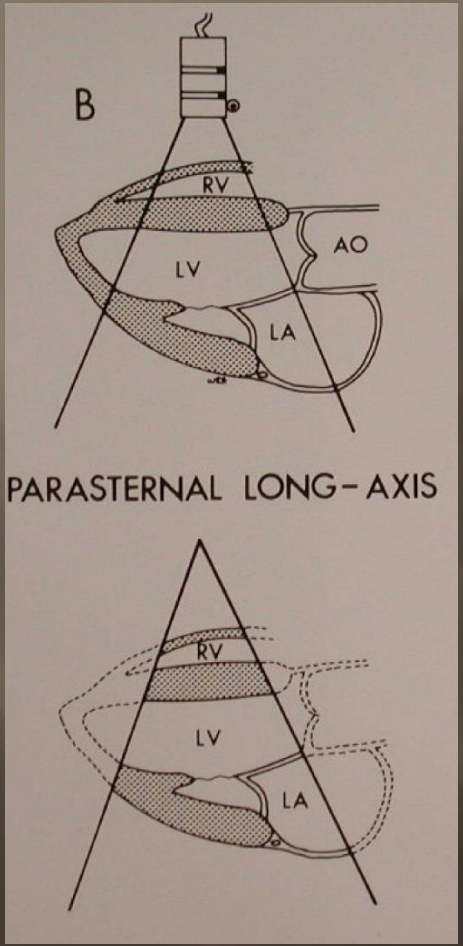


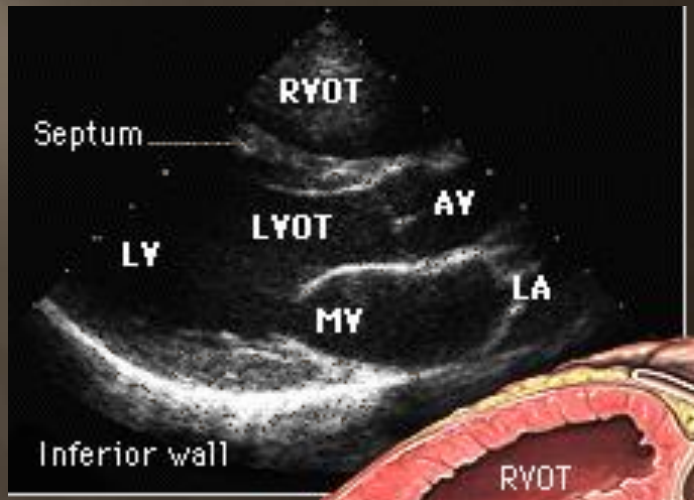


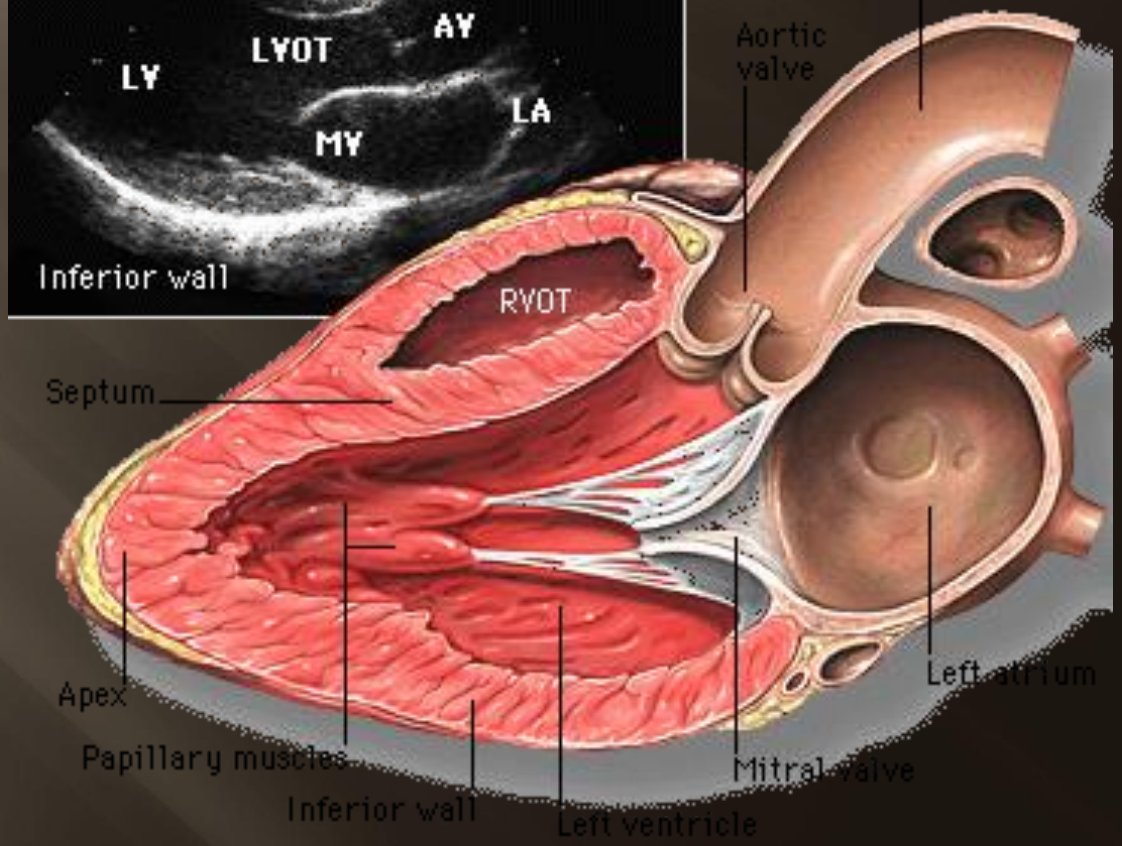

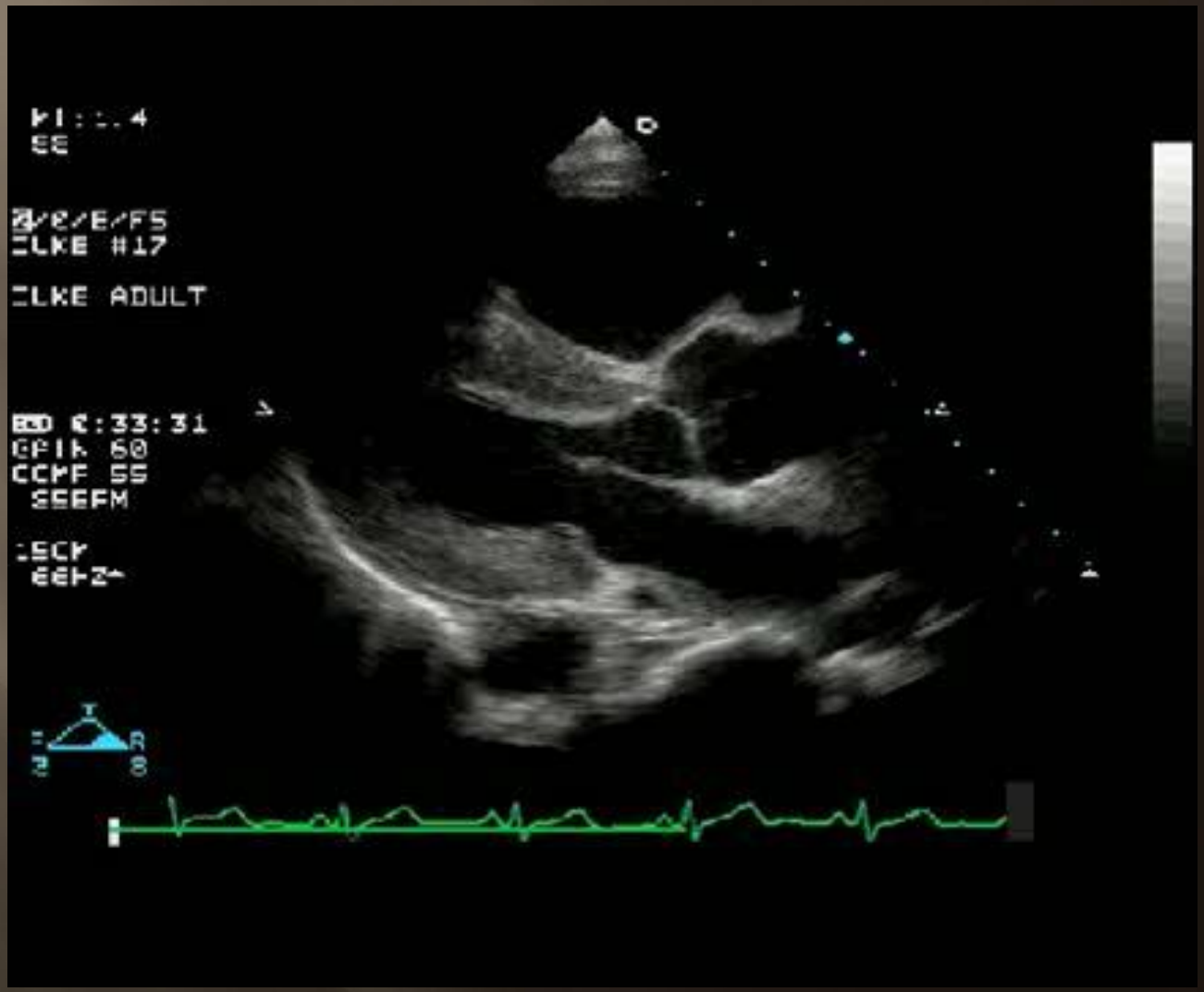
ADULT

# Parasternal Kısa aks

- Aynı yerde probun 90° döndürülür
- Prob çıkıntısı sol omuza bakar
- Apeksten kalbin basisine kadar bakılır

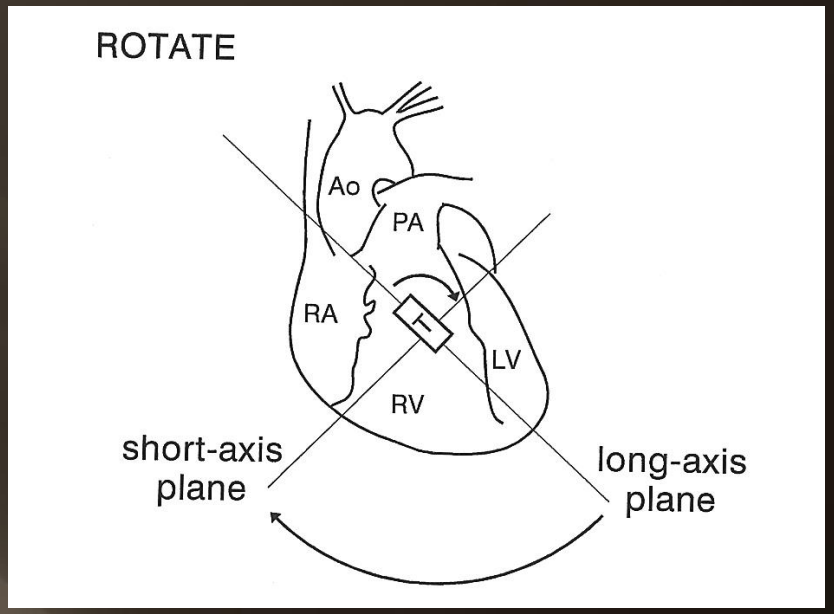

# Parasternal - Kısa aks

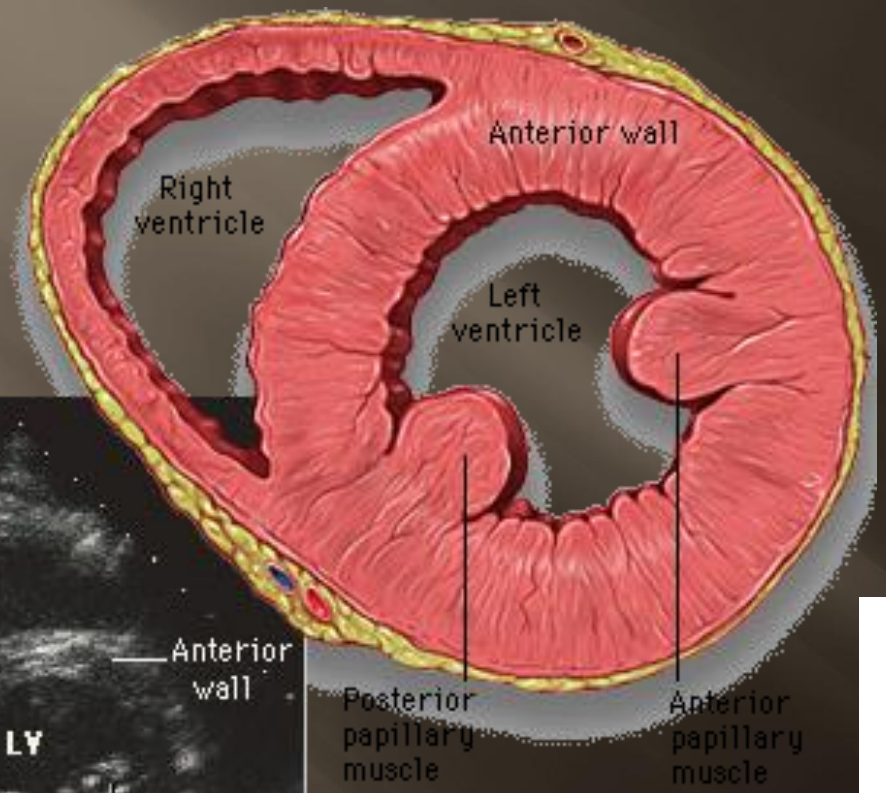


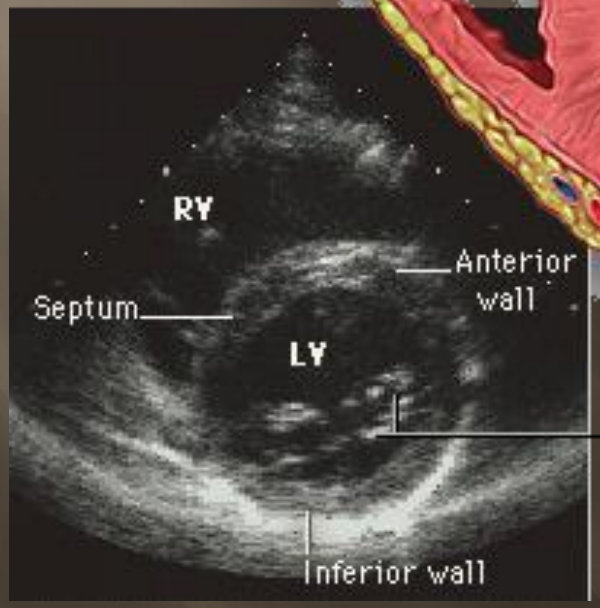


Aortik valvin yapısı
LV fonksiyonları

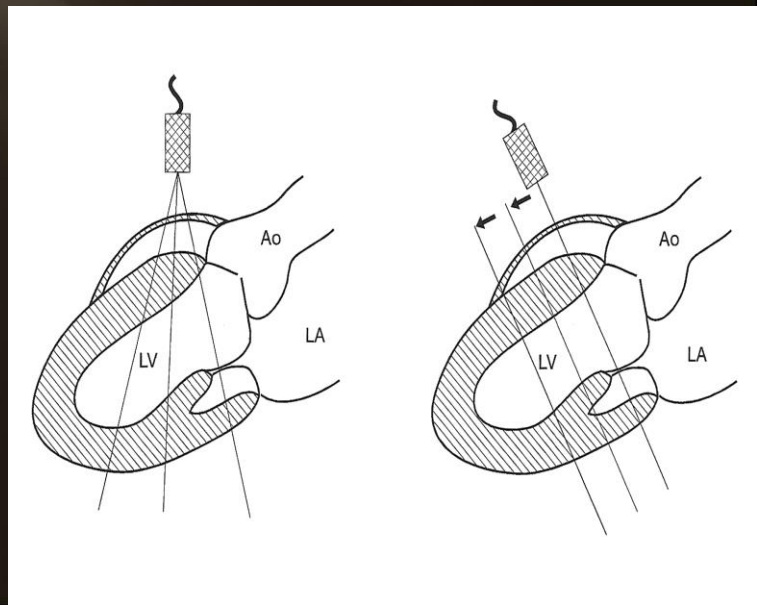

# Parasternal - Kısa aks

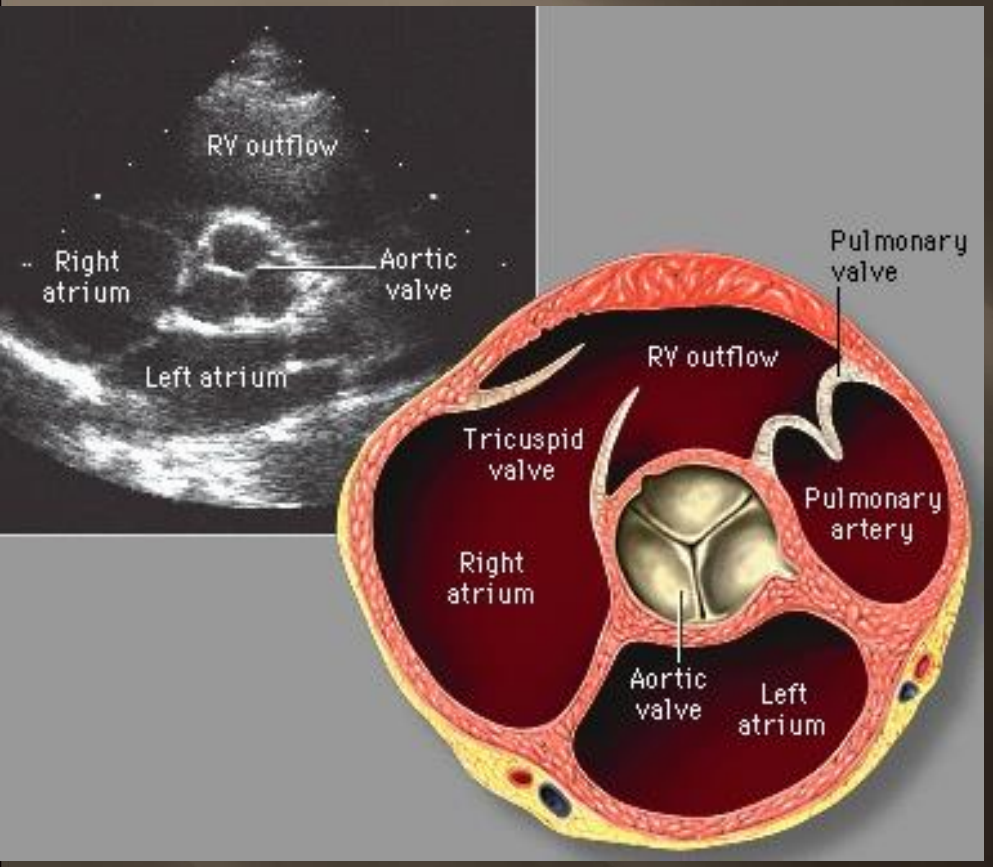


Aynı yerde probun 90° döndürülmesi ile Apeksten kalbin köküne kadar bakılır

# Apikal Yön

- Görüntülemek daha zor
- Ventrikül boyutlarını ölçmek için uygun
- Septum / duvar hareketlerini değerlendirmek için uygun

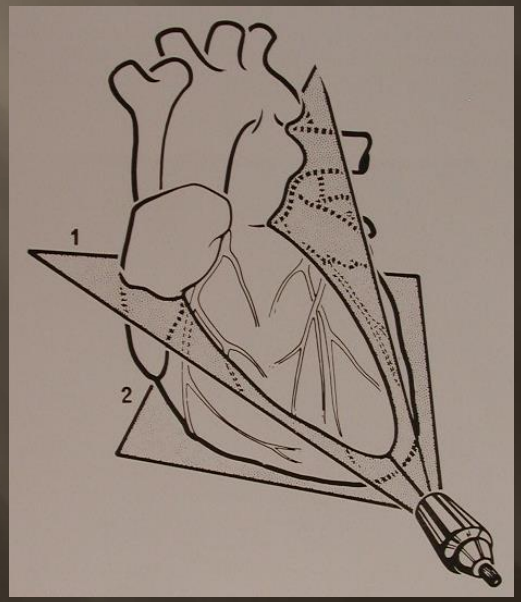


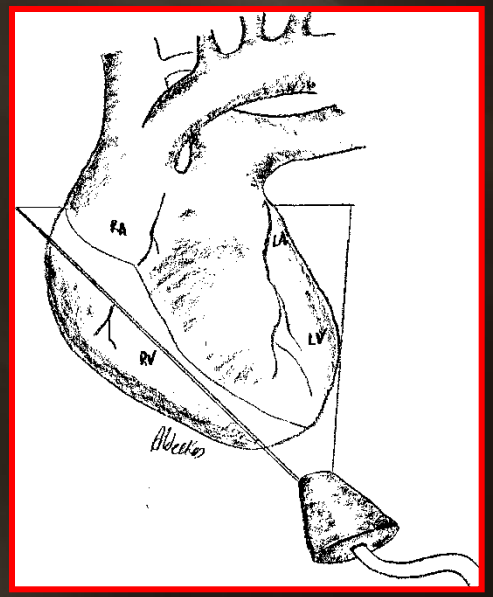

# Apikal Yön - 4 odacık

- Hasta sol lateral dekubit duruşunda
- Prob apekste
- Probun çıkıntısı aşağıya doğru,
- Parasternal yön gibi fakat apeksi

daha iyi gösterir

# Apikal Yön - 4 odacık

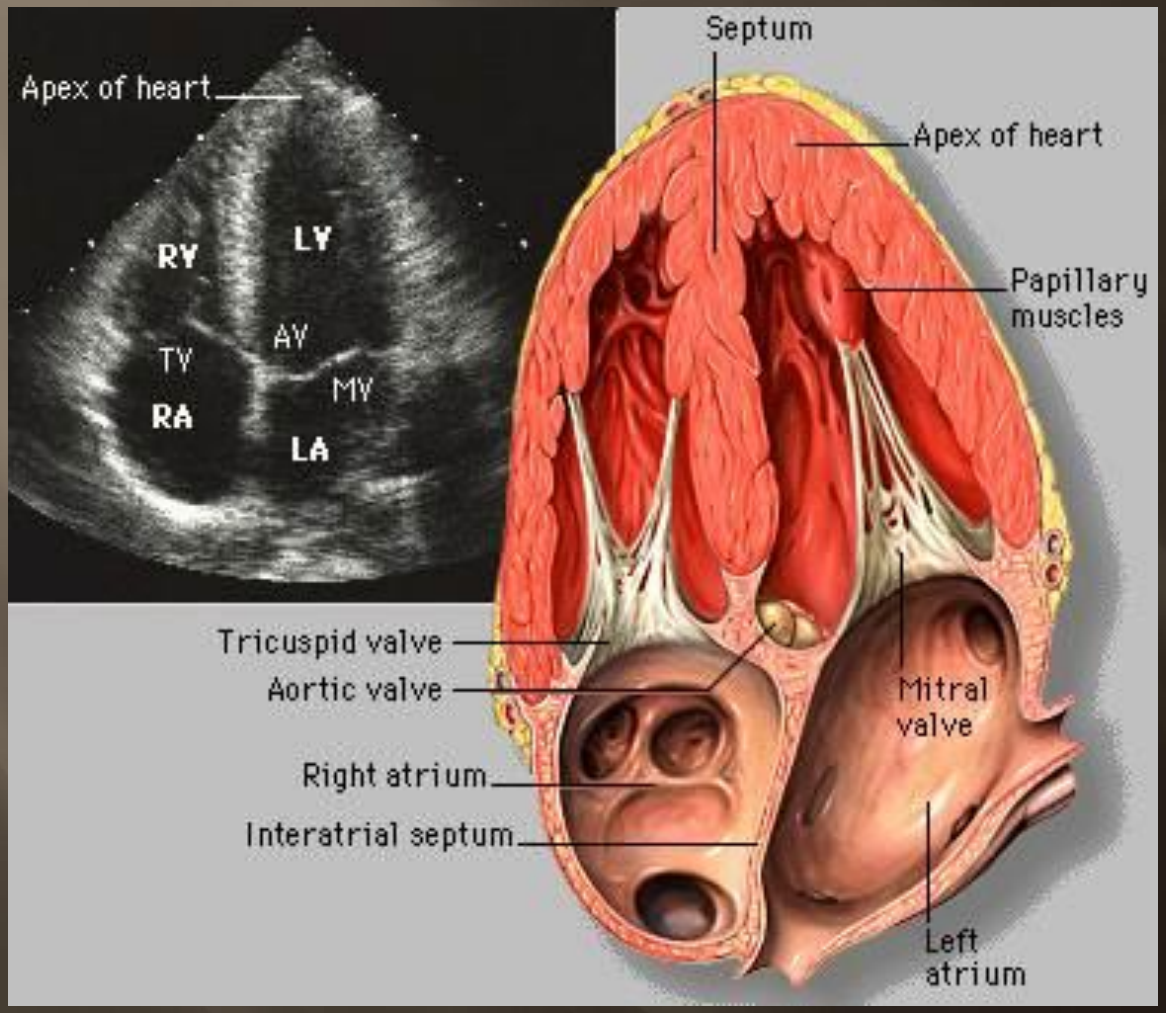


LV fonksiyonları
Atrium büyüklükleri
Kapak regürjitasyonu
Doppler

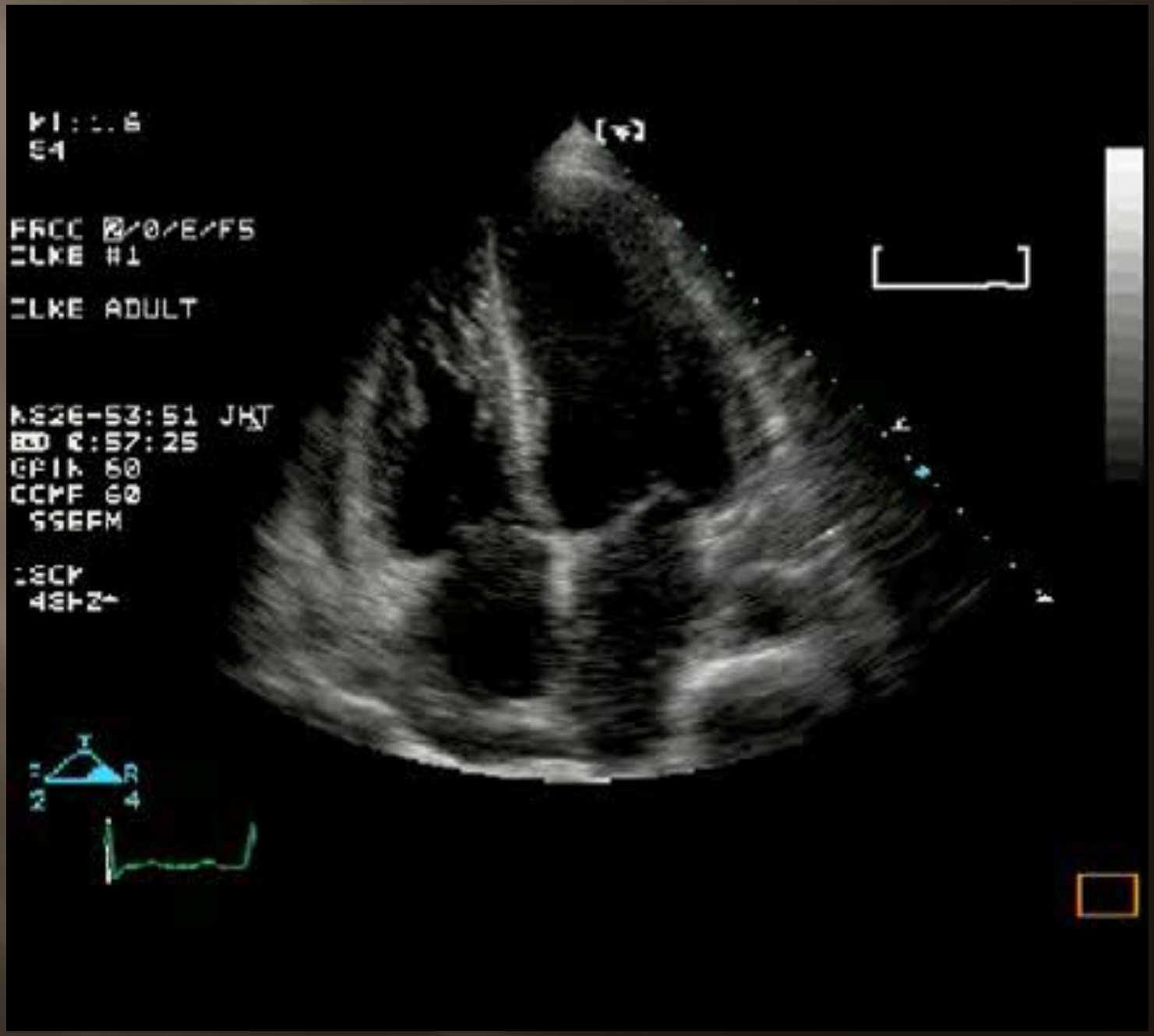
ADULT

# Apikal Yön - 2 odacık

- Prob 90° döndürülür
- Çıkıntı saat 3'e doğru
- Ant ve inf duvarlar ve mitral kapak için iyi

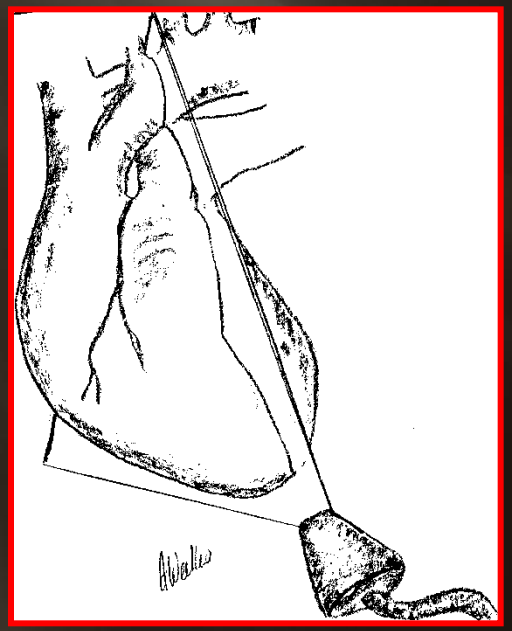

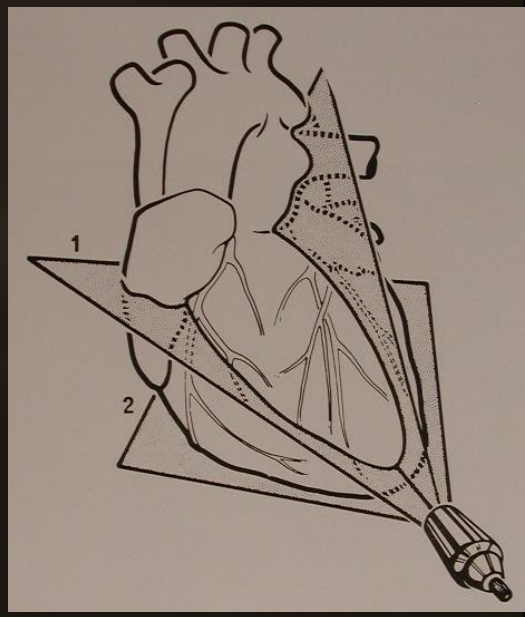

# Apikal Yön 2 odacık

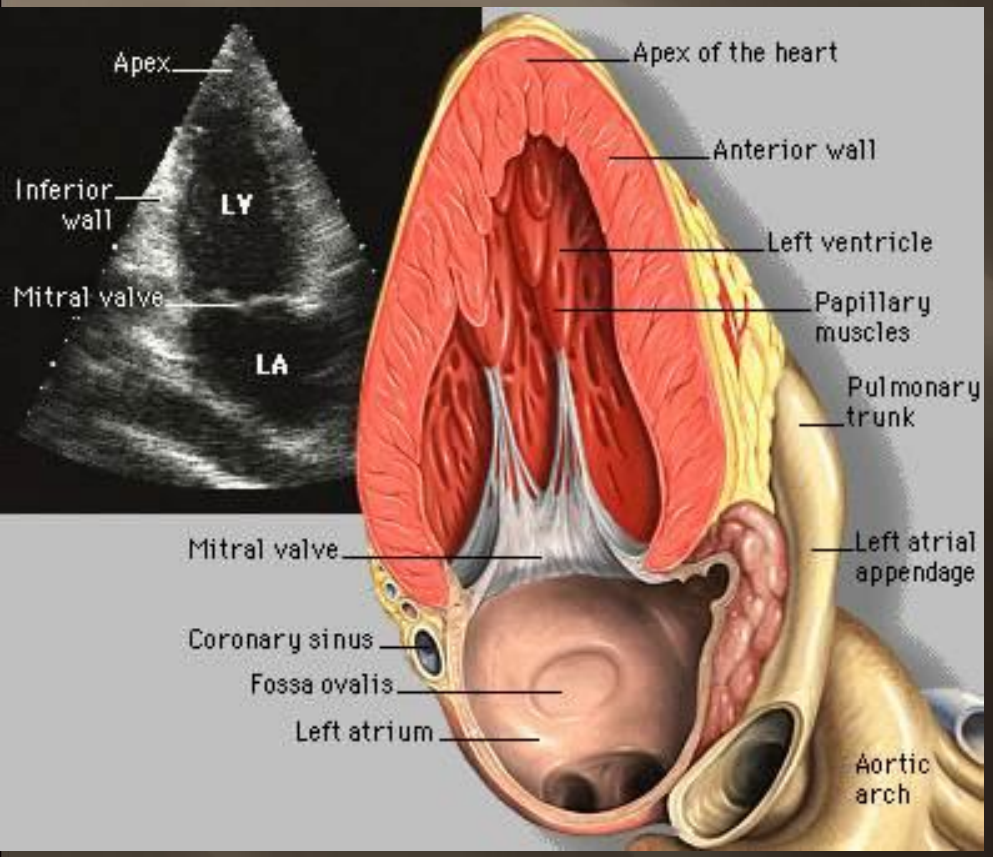


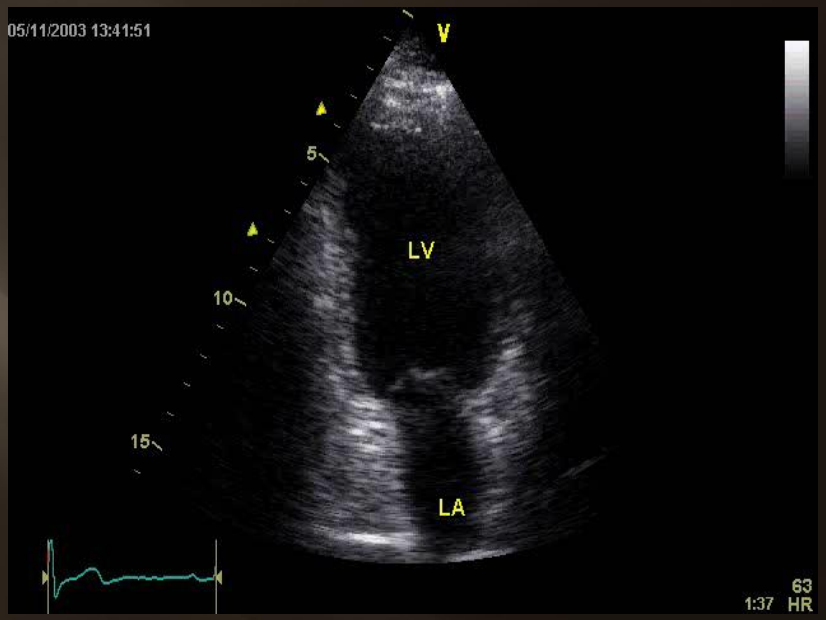


LV fonksiyonları
Kapak regürjitasyonu

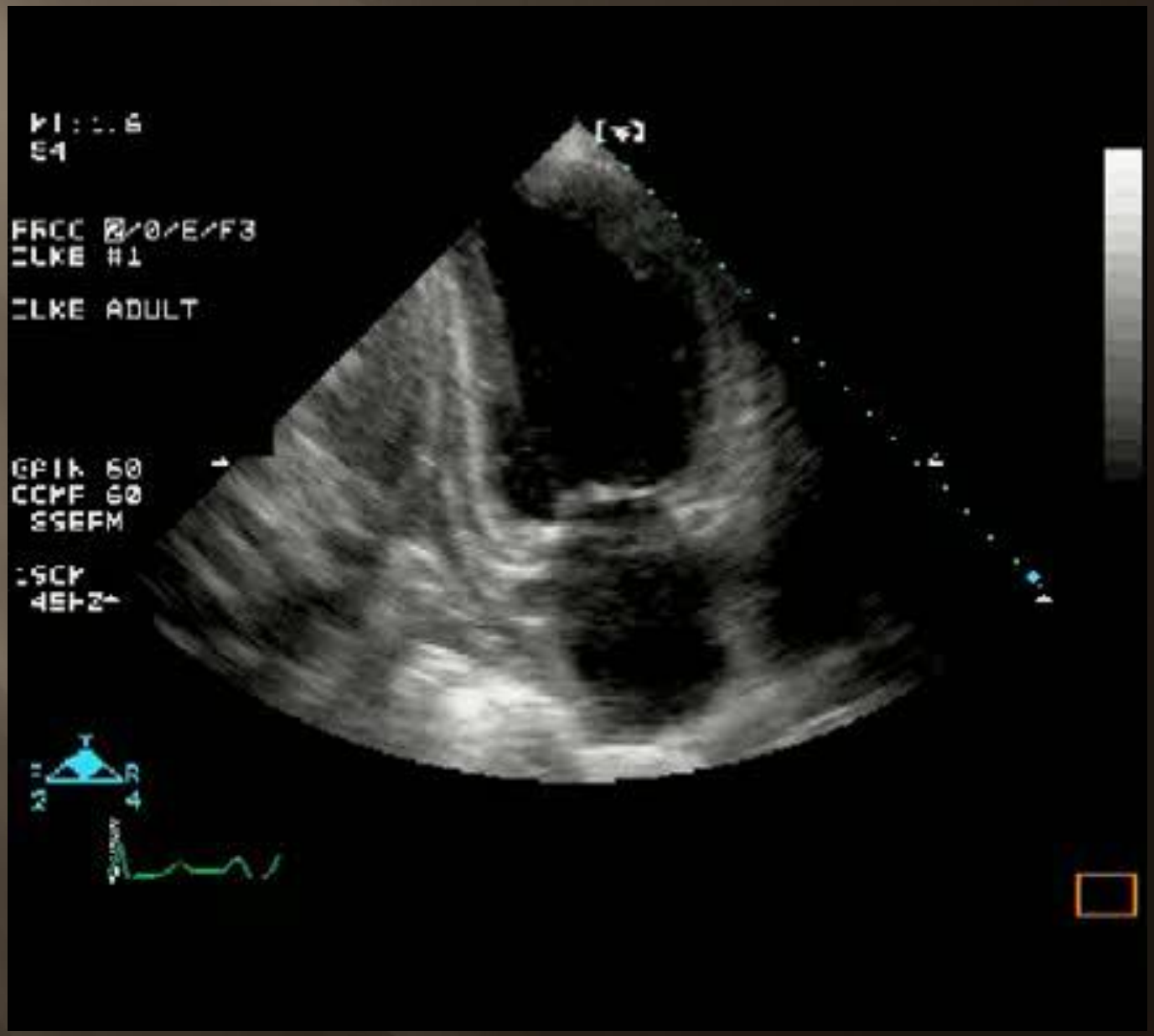
CLKE ADULT

# Subkostal (subksifoid)

- Genel değerlendirme penceresi
  - Circumferential perikardiyal effüzyon
  - Duvar hareketleri (genel olarak)
- Akustik pencere =karaciğer

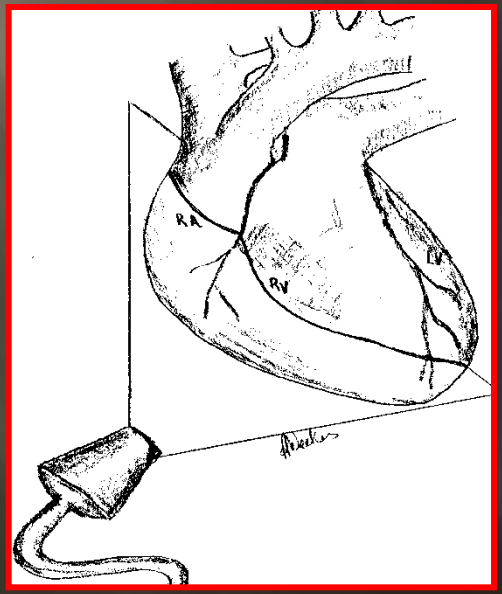

# Subkostal yön

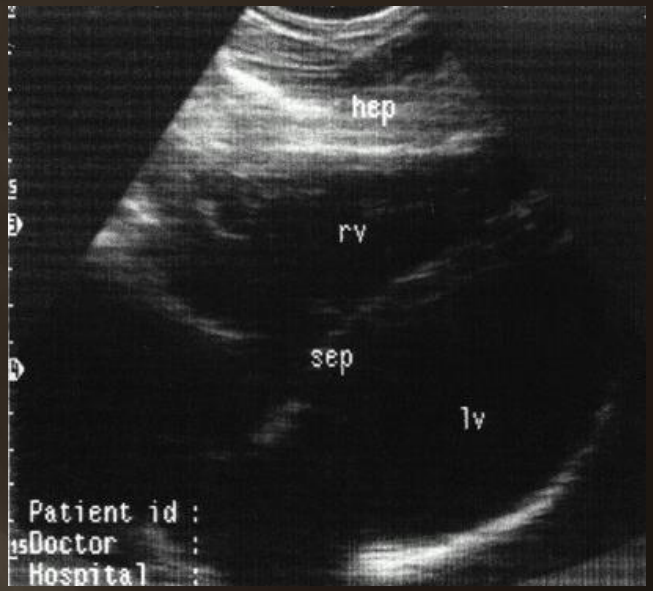

LV fonksiyonları
Perikardiyal efüzyon
VCI değerlendirilmesi

# Perikardiyal Efüzyonun Büyüklüğü

- Normal 15- 50mlt
- Küçük: arkada, <0.5 cm
- Orta: ant. ve posterior, diastolde 0.5-2 cm
- Büyük: >2 cm

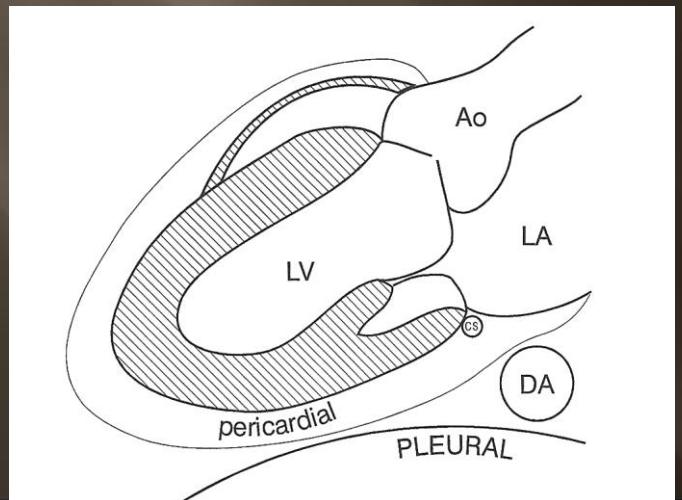

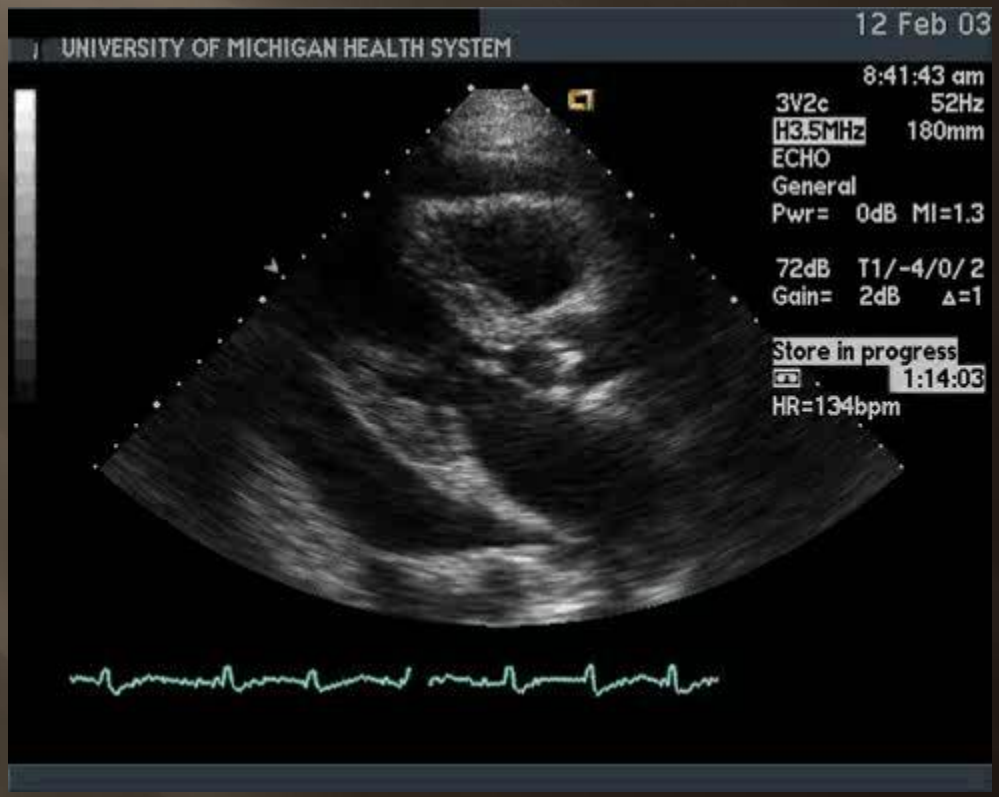
UNIVERSITY OF MICHIGAN HEALTH SYSTEM
12 Feb 03
8:41:43 am
3V2c
52Hz
H3.5MHz
180mm
ECHO
General
Pwr= 0dB MI=1.3
72dB T1/-4/0/2
Gain= 2dB Δ=1
Store in progress
1:14:03
HR=134bpm

# Teknik sorunlar

- Ciltaltı amfizem
- Pnömoperikardiyum
- Mekanik ventilasyon
- Kısıtlayıcı etkenler:
  - Ağrı / hassasiyet
  - Spinal korumaların uygulanması
  - Diğer acil girişimler
- Dar interkostal aralıklar
- Şişmanlık
- Kaslı göğüs
- KOAH
- Kalsifiye kot kıkırdakları
- Abdominal distansiyon

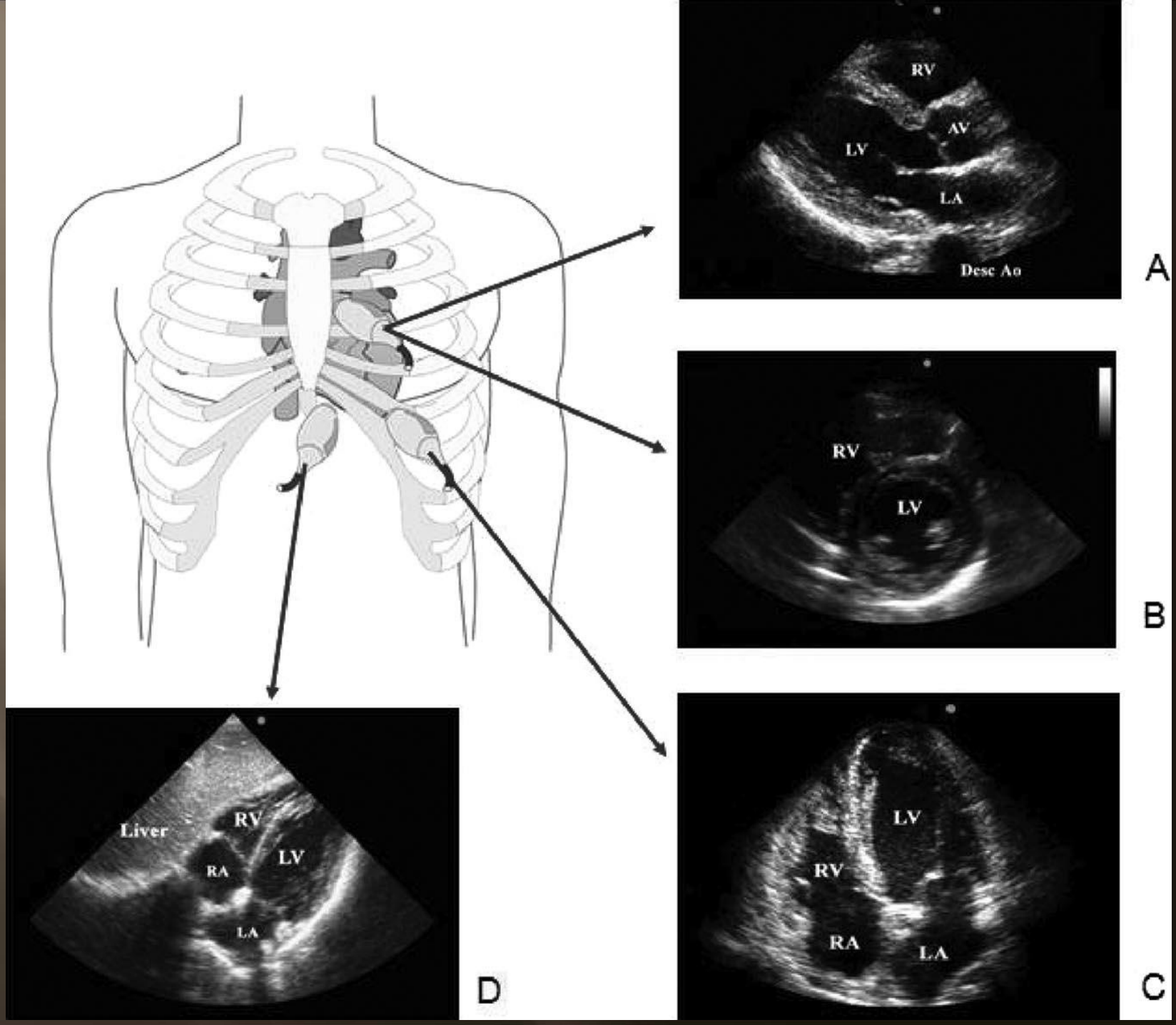
RV
AV
LV
LA
Desc Ao
A
RV
LV
B
LV
RV
RA
LA
C
Liver
RV
LV
RA
LA
D

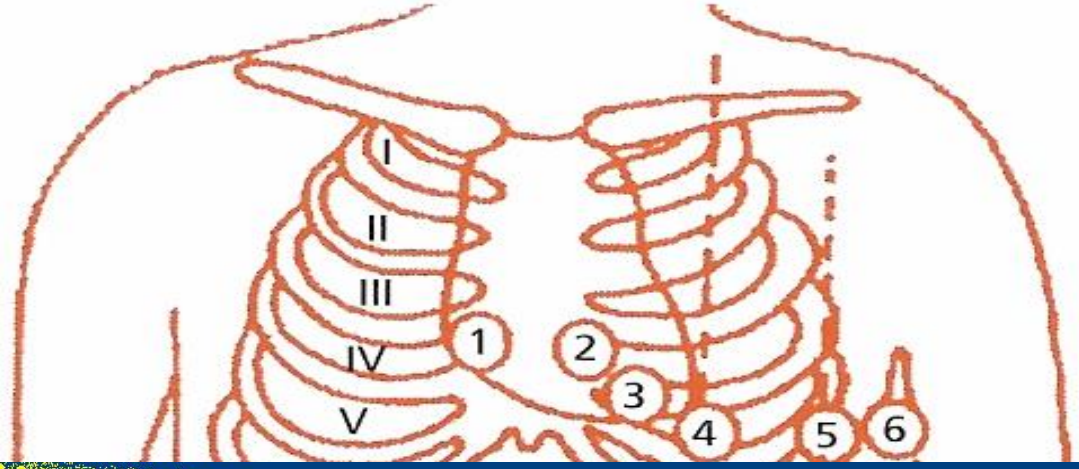
I
II
III
IV
V
1
2
3
4
5
6

OLD TRAFFORD - Manchester/England
Capasity : 72.000
Made By _Marx_

V1
V2
V3
V4
V5

# Duvar hareketleri

**LAD** (Sol Ant. Des.)

- Ant. duvar
- Ant. Septum
- Mid-Apikal Sep

**RCA** (Sağ koroner A.)

- İnf.Duvar
- Septumun basali

**Cx** (cirkümflex)

- Lateral duvar
- Posterior duvar

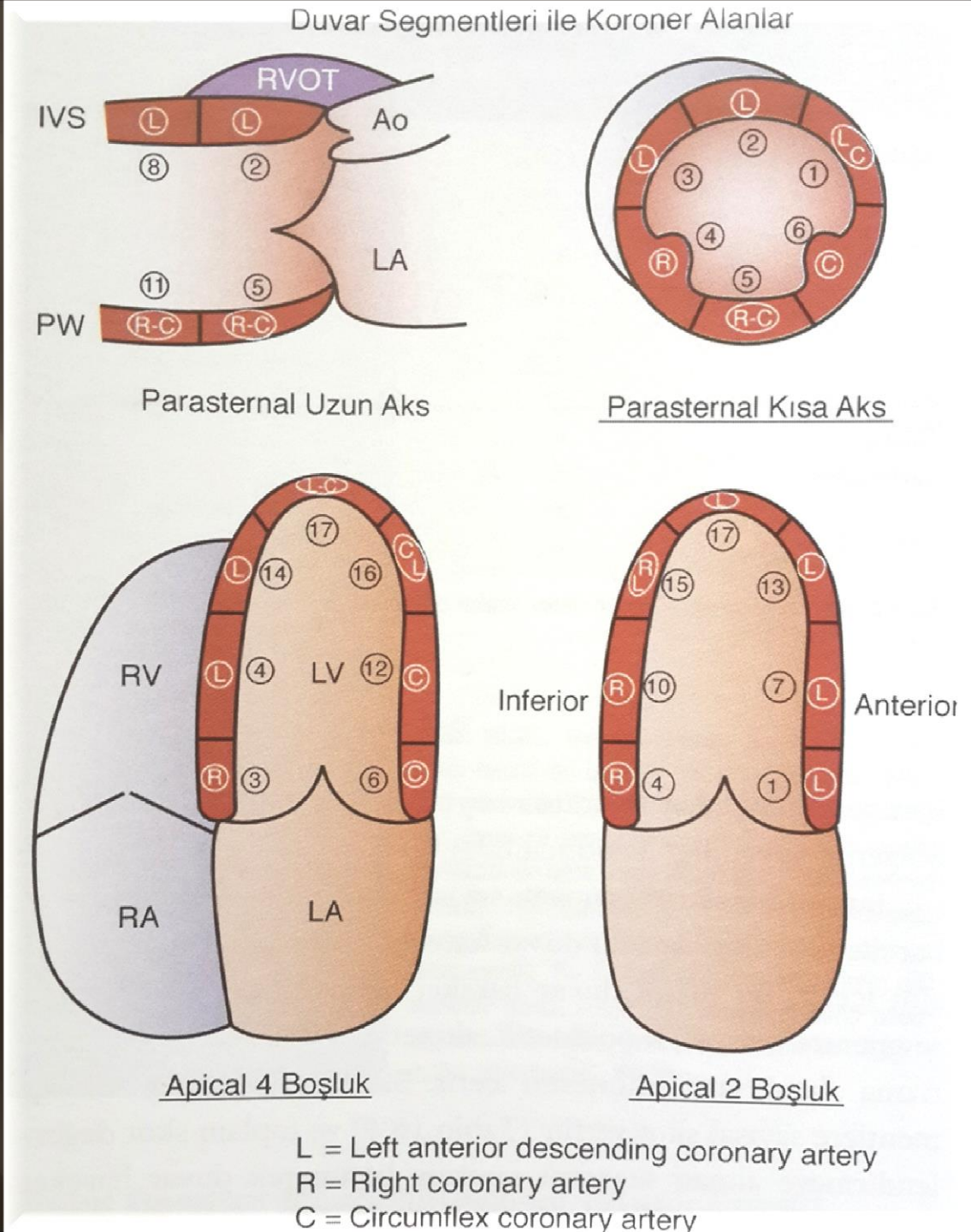

# AKS düşünülen hastada

- Semptomlar atipikse
- EKG yetersizse
- Kardiak biomarkerlar negetifse

KARDİAK EKO kullanılmalıdır

# Algorhythm of Chest Pain Assessment in ER

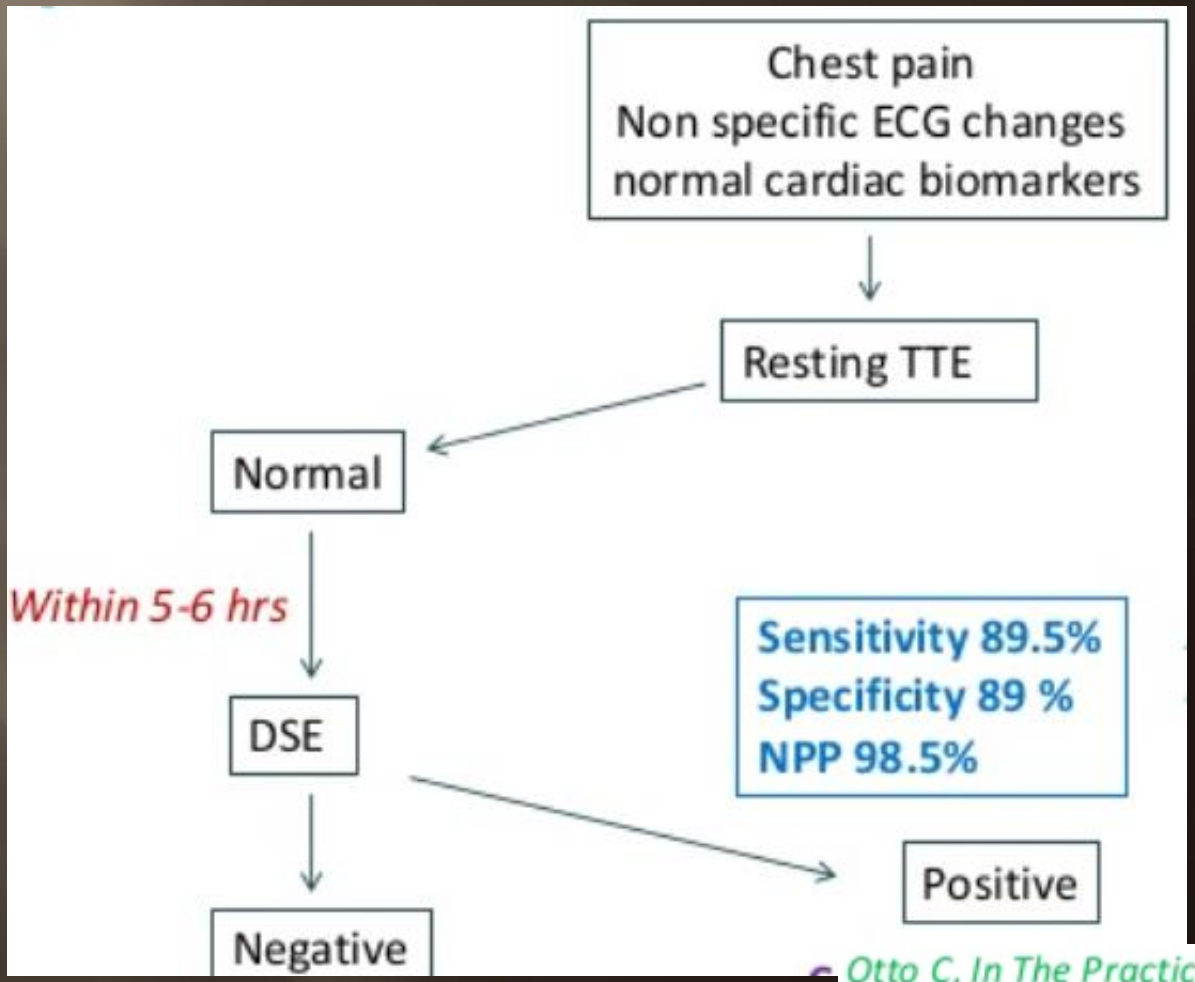


*Otto C. In The Practice of Clinical Echocardiography 2012*

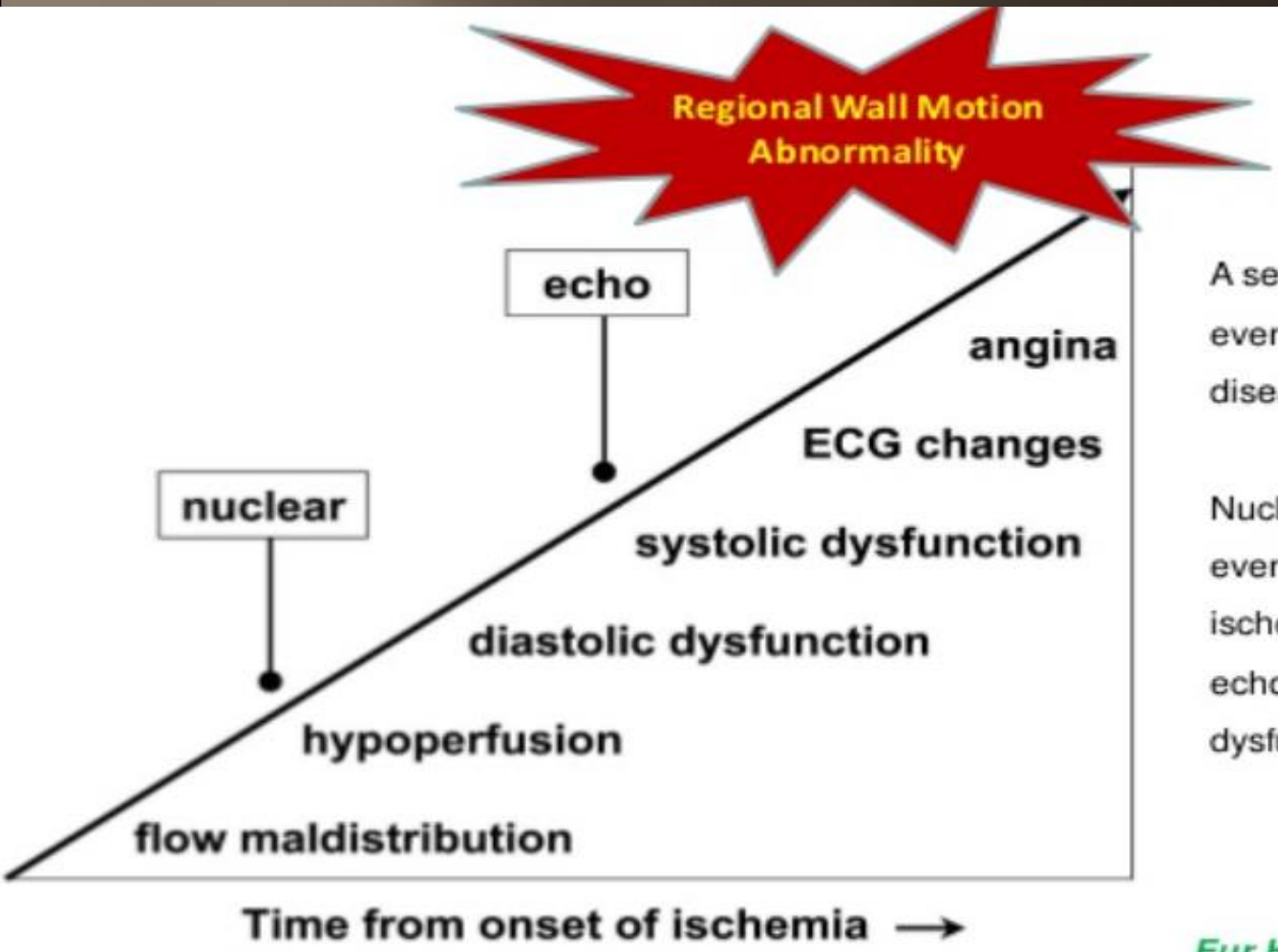


A sequence of pathophysiologic events caused by coronary artery disease.

Nuclear imaging probes an earlier event (hypo-perfusion) in the ischemic cascade than stress echocardiography does (systolic dysfunction).

*Eur Heart J 2003 ; 24 (9) 789-800*

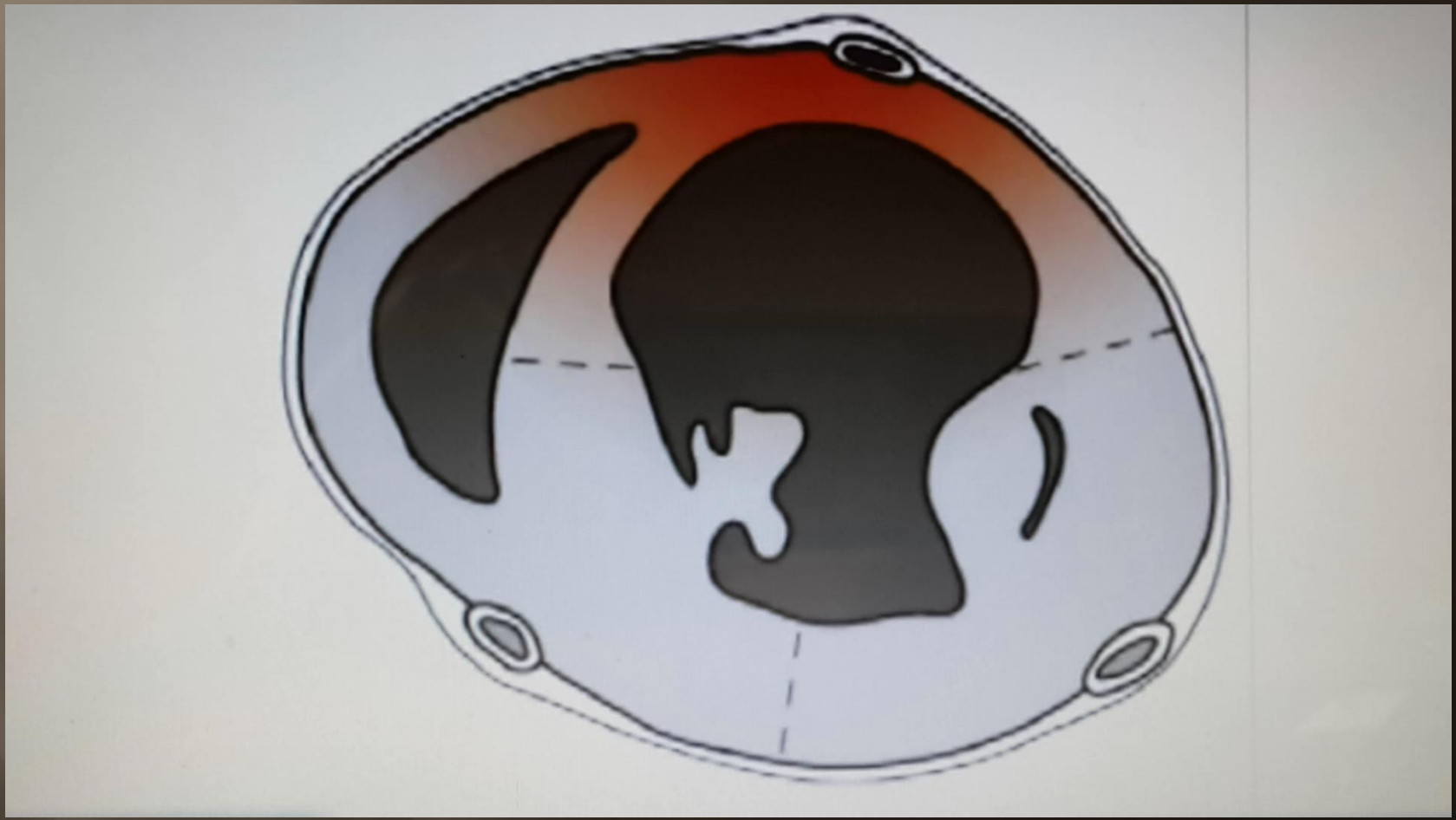

# Regional Wall Motion Abnormality (RWMA)

Bölgesel Duvar Hareket bozuklukları

1. Duvar kalınlaşması
2. RWMA MI ve iskemi için karakteristiktir
3. İnfarktın olduğu yerde patoloji görülür, dagılımın iyi olduğu yerde hareket normal

# Hareket Bozukluğu

- Hybernation?
- Stunning?
- İskemik preconditioning?

# AKS'lu hastada açıklanamayan hemodinamik durum değişikliklerinde

EKO'DA

- Vent. Sept. Rüptür,
- M. Papillaris rüptürü,
- Serbest Duvar Rüptürü,
- Dresler Sendromu,
- Apikal anevrizma+trombüs,
- Sağ vent. infarktı

# Anterior

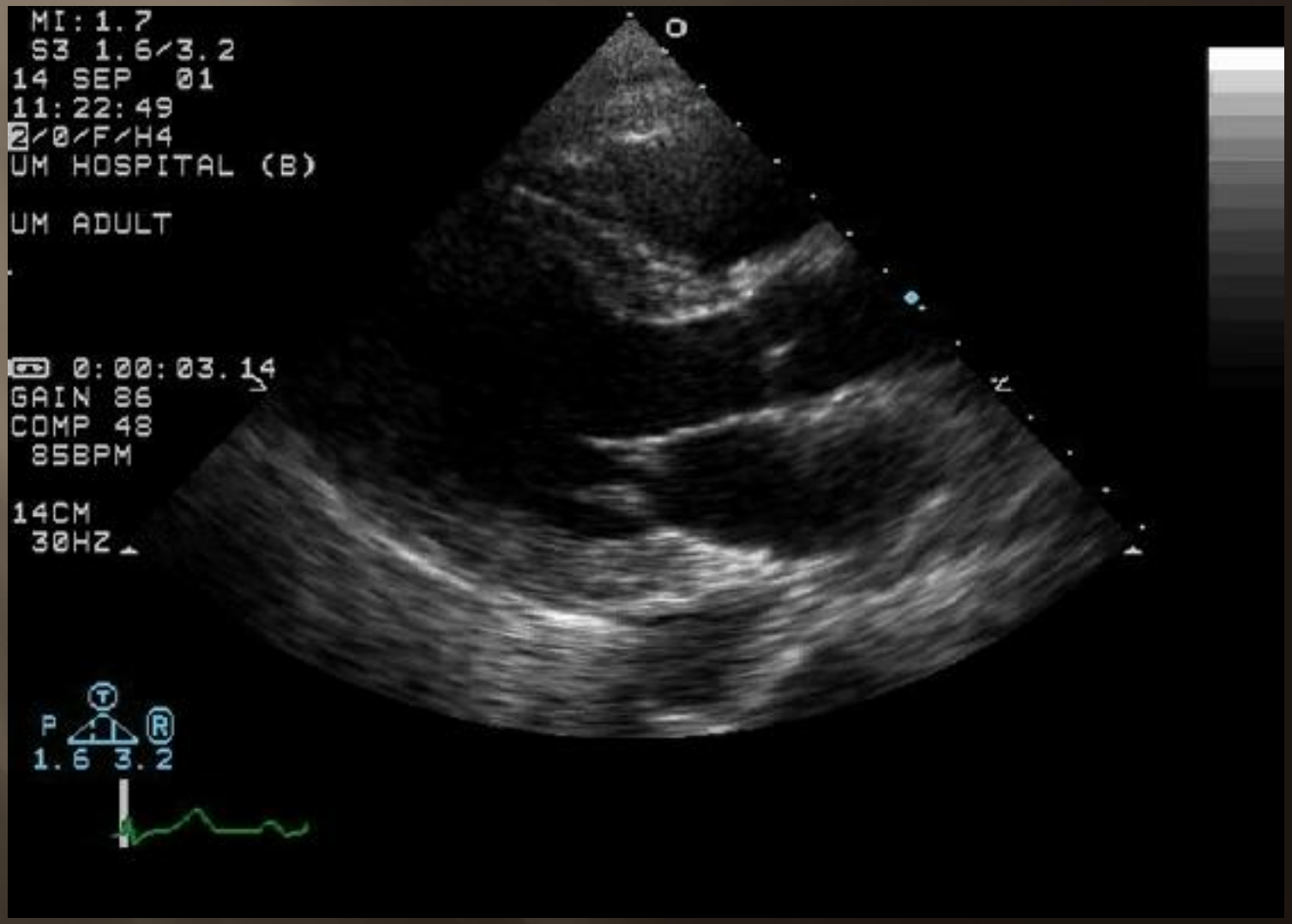
MI: 1.7
S3 1.6/3.2
14 SEP 01
11:22:49
2/0/F/H4
UM HOSPITAL (B)
UM ADULT
0:00:03.14
GAIN 86
COMP 48
85BPM
14CM
30HZ
T
P
R
1.6 3.2

# Yaygın Anterior

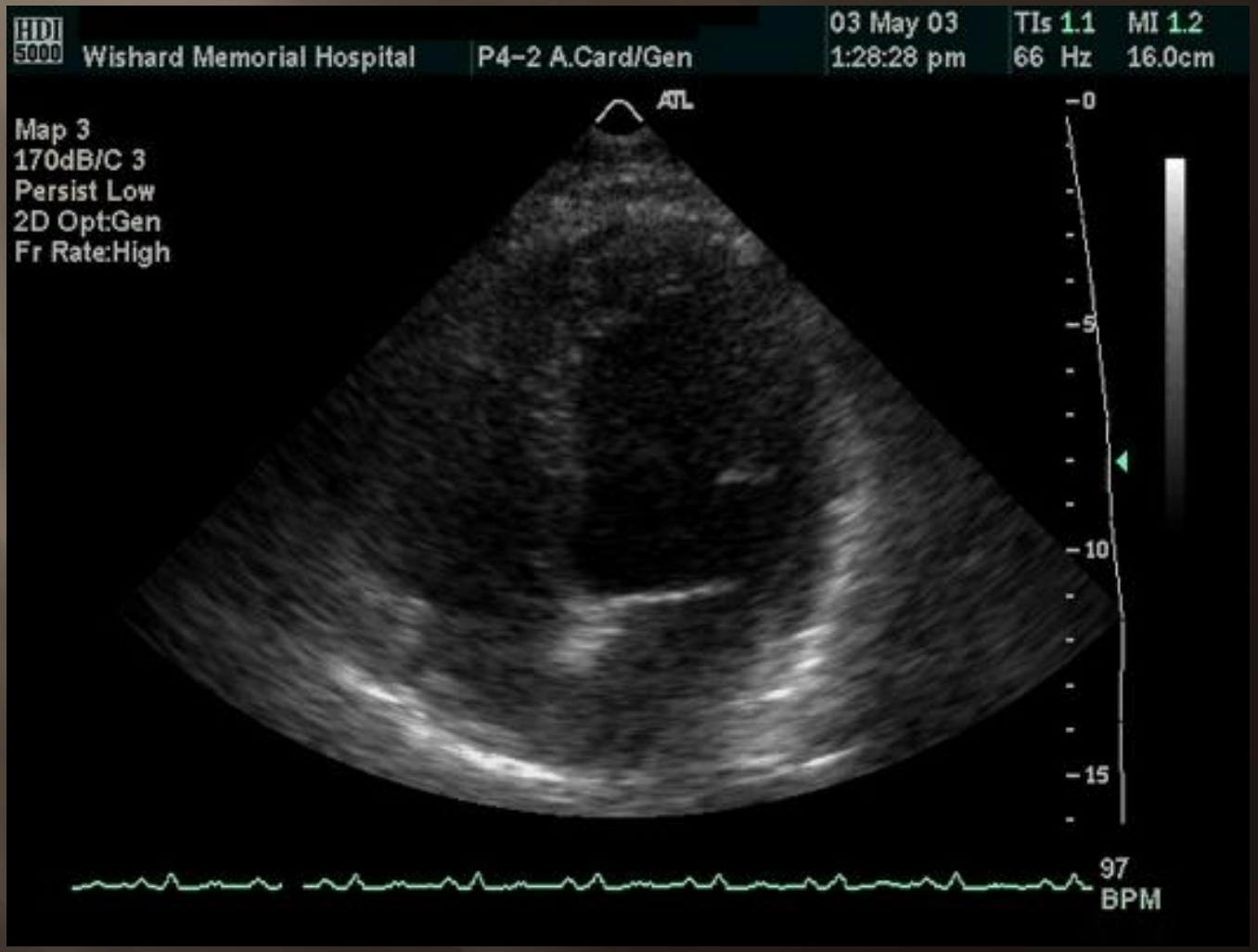

# Apikal Diskinezi 3B

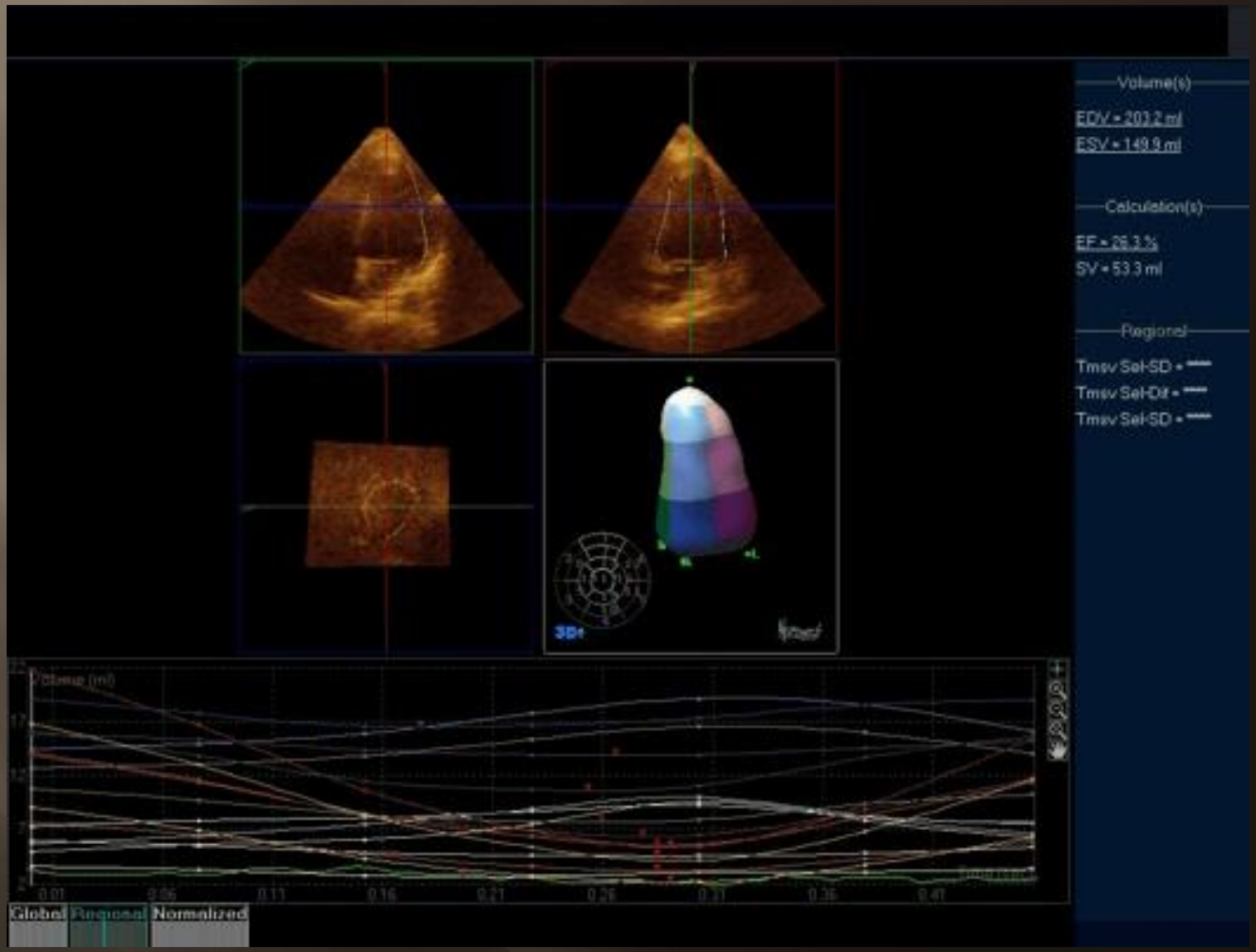

# Apikal Diskinezi

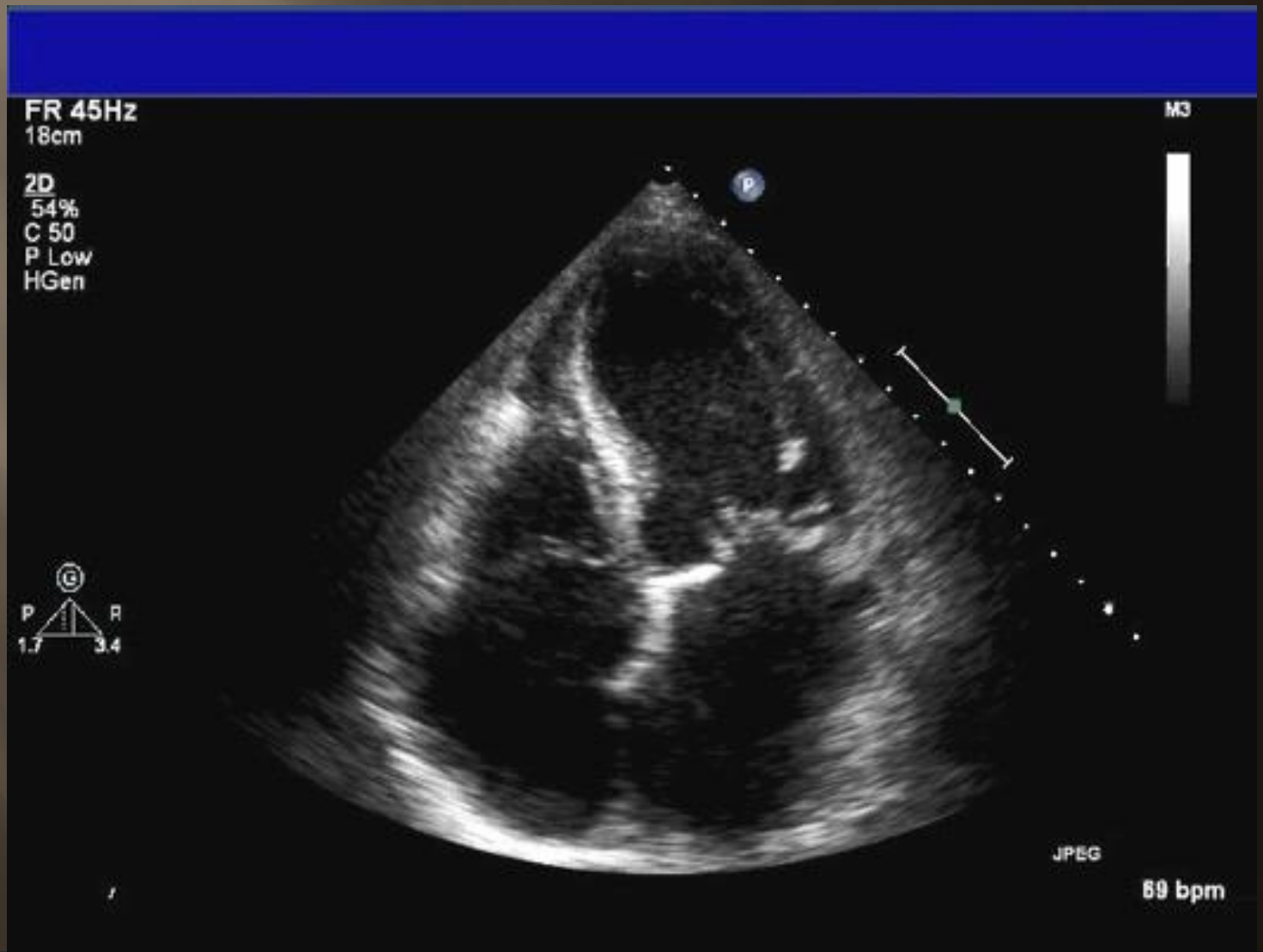

# Antero Apikal Anevrizma

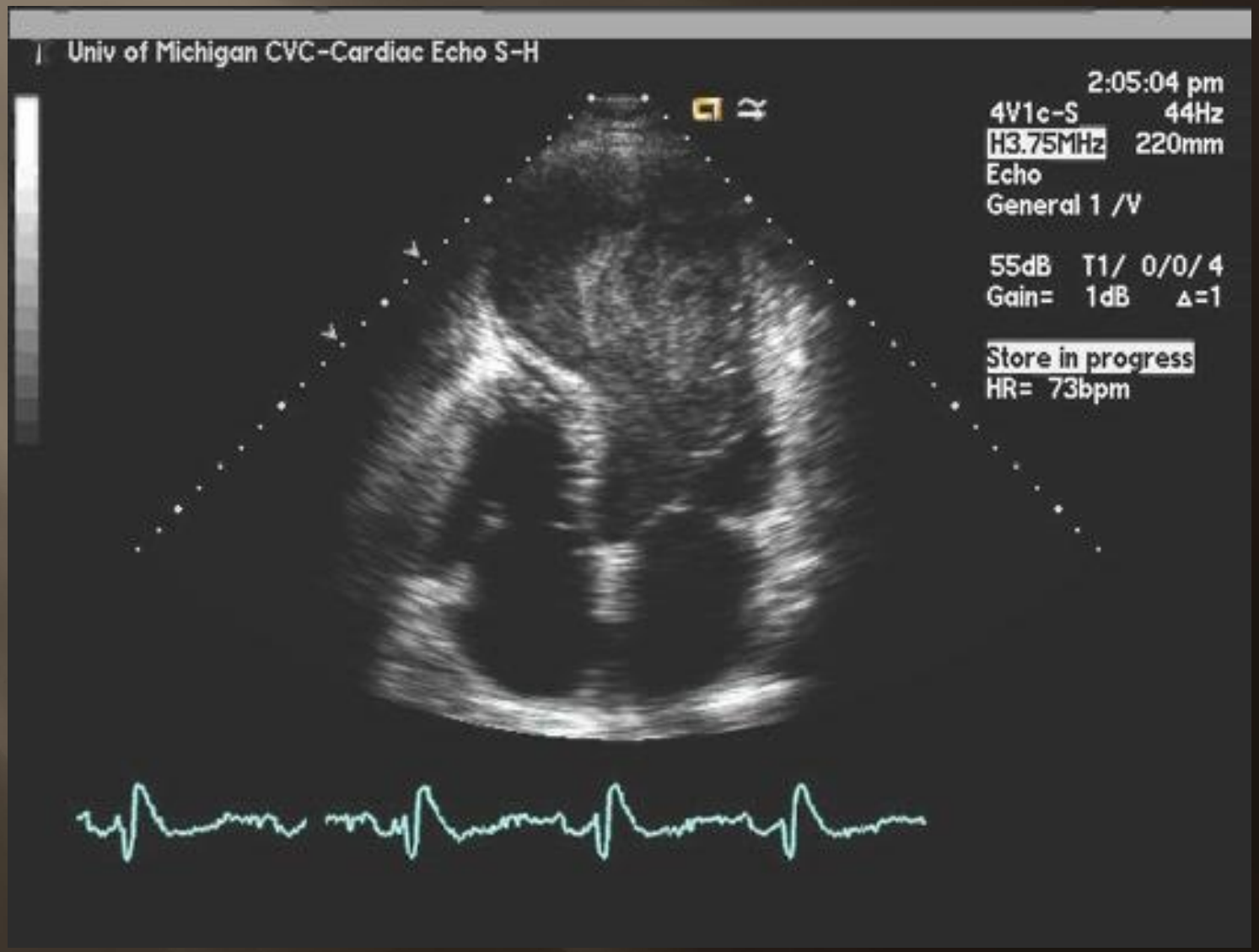

# İnferior

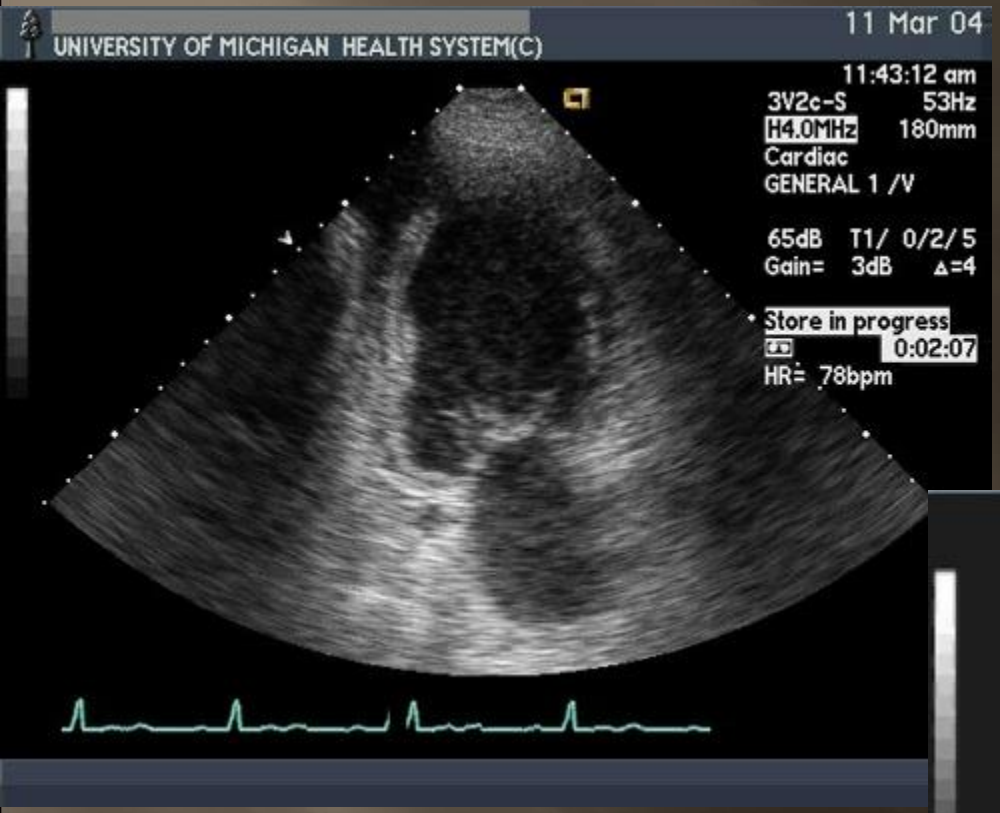
UNIVERSITY OF MICHIGAN HEALTH SYSTEM(C)
11 Mar 04
11:43:12 am
3V2c-S 53Hz
H4.0MHz 180mm
Cardiac
GENERAL 1 /V
65dB T1/ 0/2/5
Gain= 3dB Δ=4
Store in progress
0:02:07
HR= 78bpm

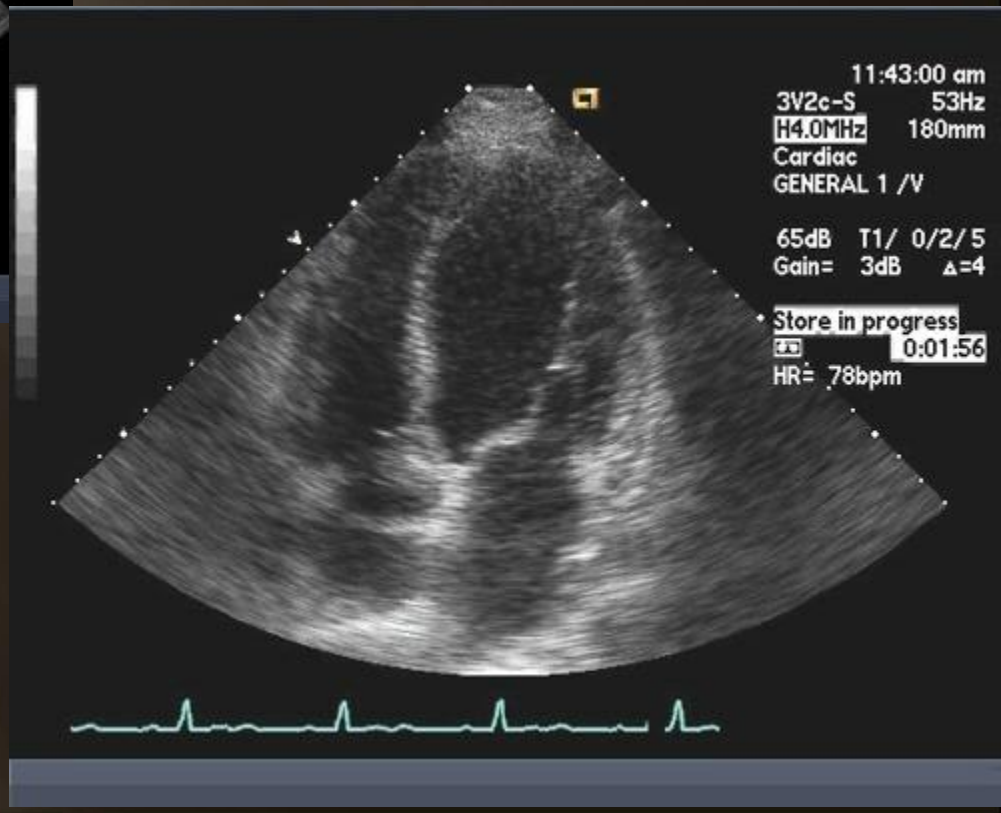
11:43:00 am
3V2c-S 53Hz
H4.0MHz 180mm
Cardiac
GENERAL 1 /V
65dB T1/ 0/2/5
Gain= 3dB Δ=4
Store in progress
0:01:56
HR= 78bpm

# İnferior Anevrizma

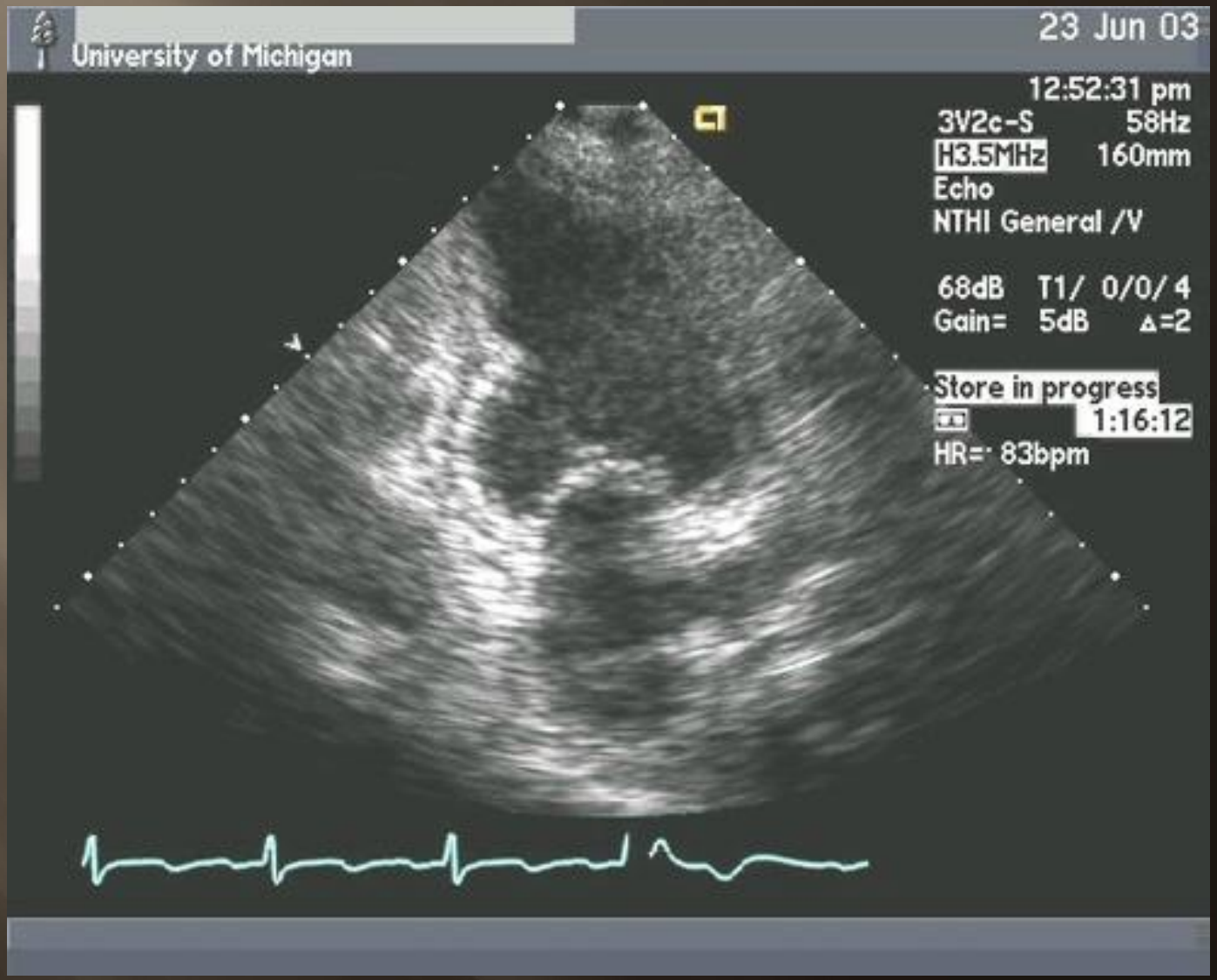

# Sağ Vent. MI

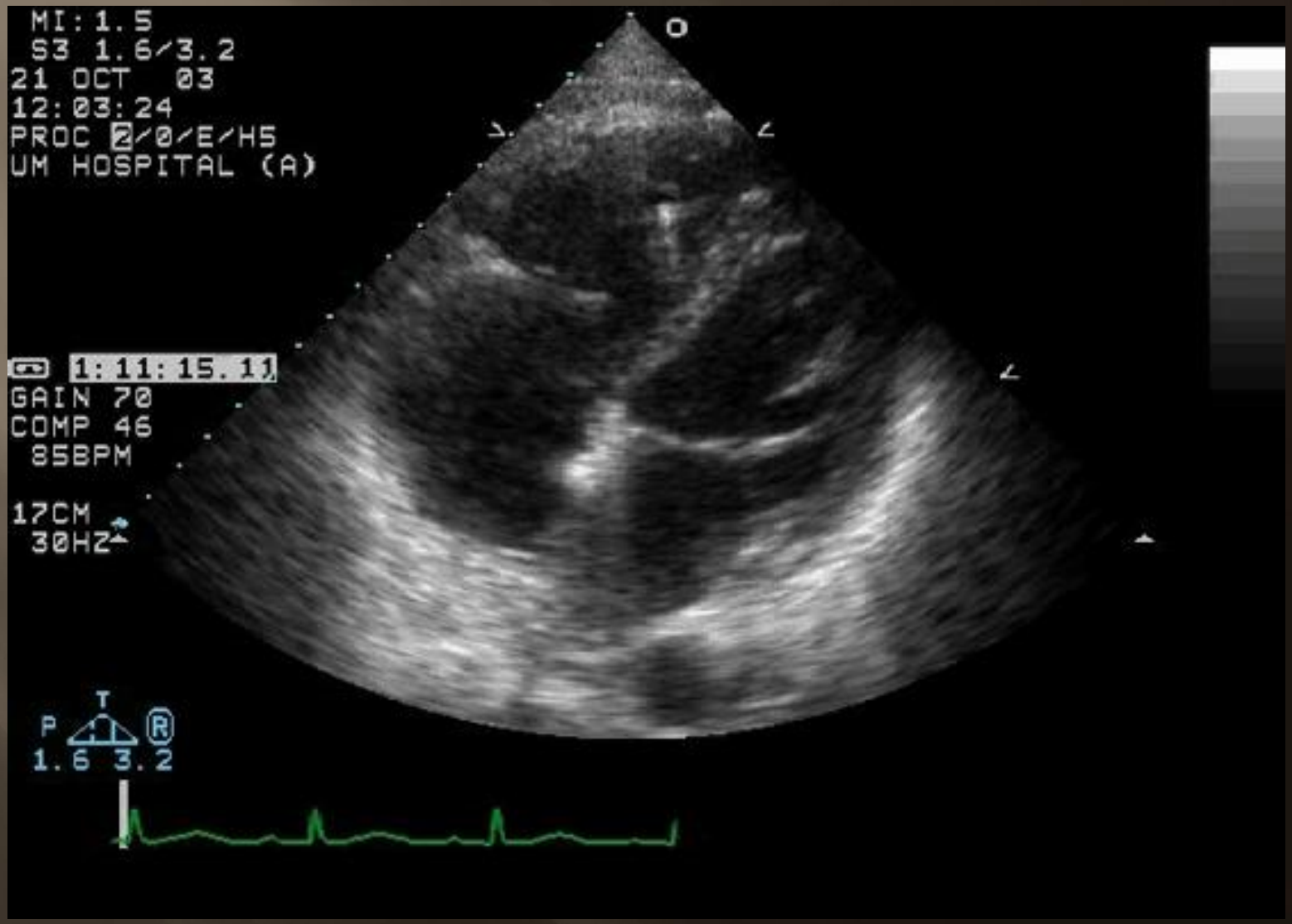
MI:1.5
S3 1.6/3.2
21 OCT 03
12:03:24
PROC 2/0/E/H5
UM HOSPITAL (A)
1:11:15.11
GAIN 70
COMP 46
85BPM
17CM
30HZ
T
P
R
1.6 3.2

# Dilate KMP

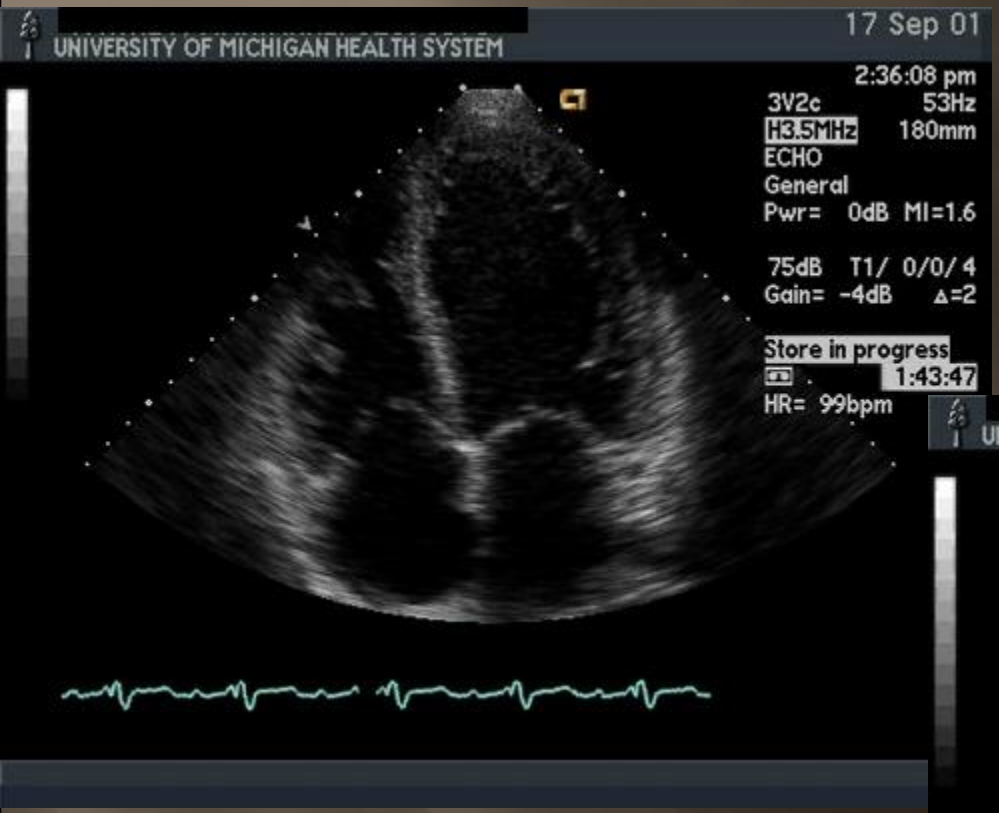
[redacted]
UNIVERSITY OF MICHIGAN HEALTH SYSTEM
17 Sep 01
2:36:08 pm
3V2c 53Hz
H3.5MHz 180mm
ECHO
General
Pwr= 0dB MI=1.6
75dB T1/ 0/0/ 4
Gain= -4dB Δ=2
Store in progress
1:43:47
HR= 99bpm

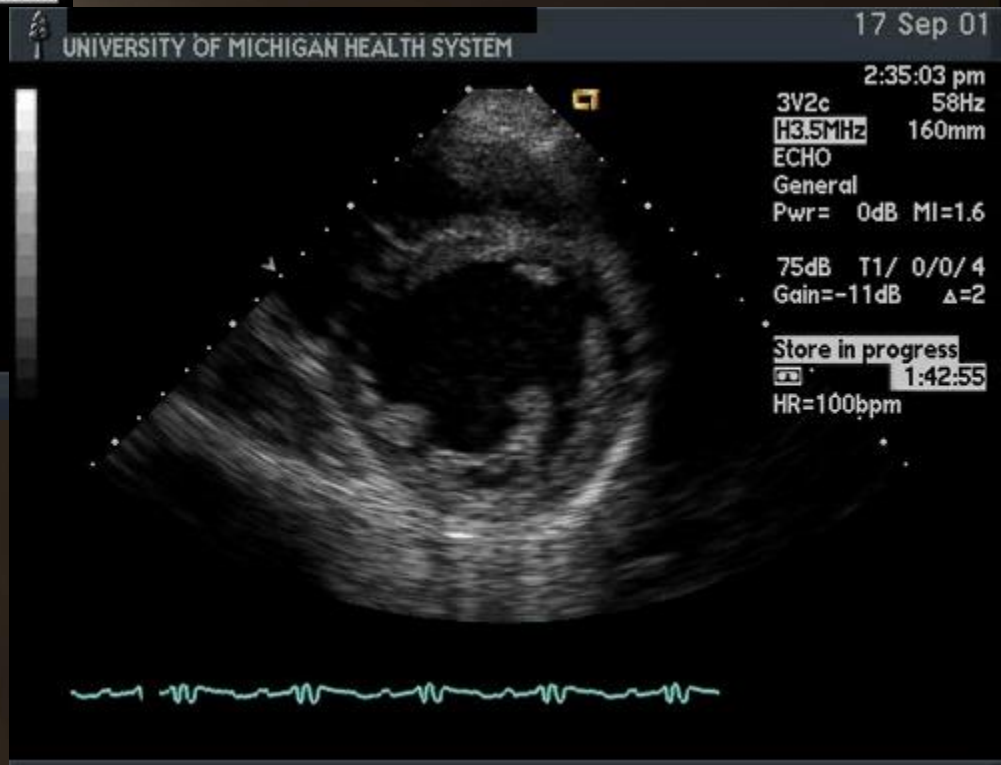
[redacted]
UNIVERSITY OF MICHIGAN HEALTH SYSTEM
17 Sep 01
2:35:03 pm
3V2c 58Hz
H3.5MHz 160mm
ECHO
General
Pwr= 0dB MI=1.6
75dB T1/ 0/0/ 4
Gain=-11dB Δ=2
Store in progress
1:42:55
HR=100bpm

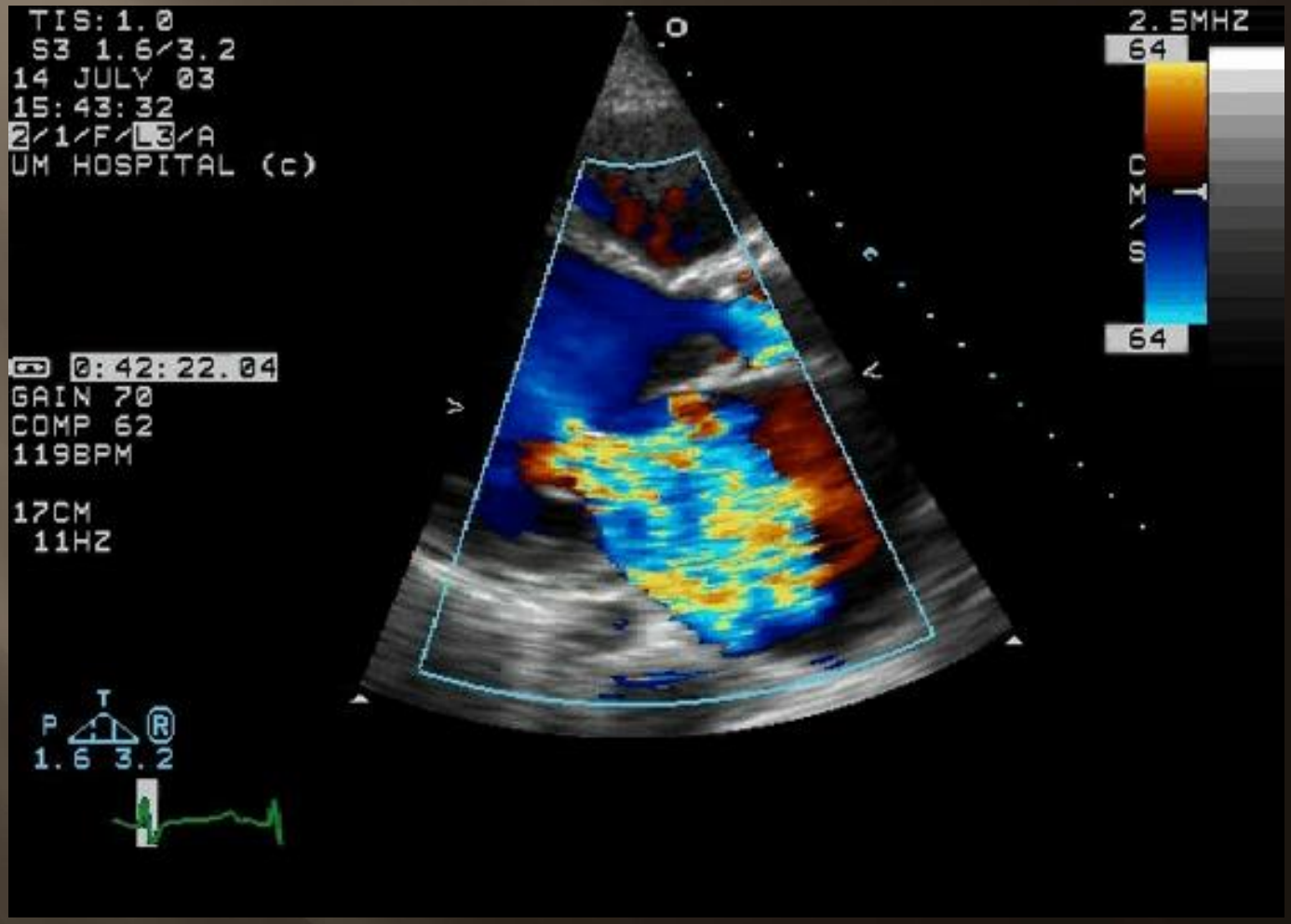
TIS:1.0
S3 1.6/3.2
14 JULY 03
15:43:32
2/1/F/L3/A
UM HOSPITAL (c)
0:42:22.04
GAIN 70
COMP 62
119BPM
17CM
11HZ
P
T
R
1.6 3.2
2.5MHZ
64
CM/S
64

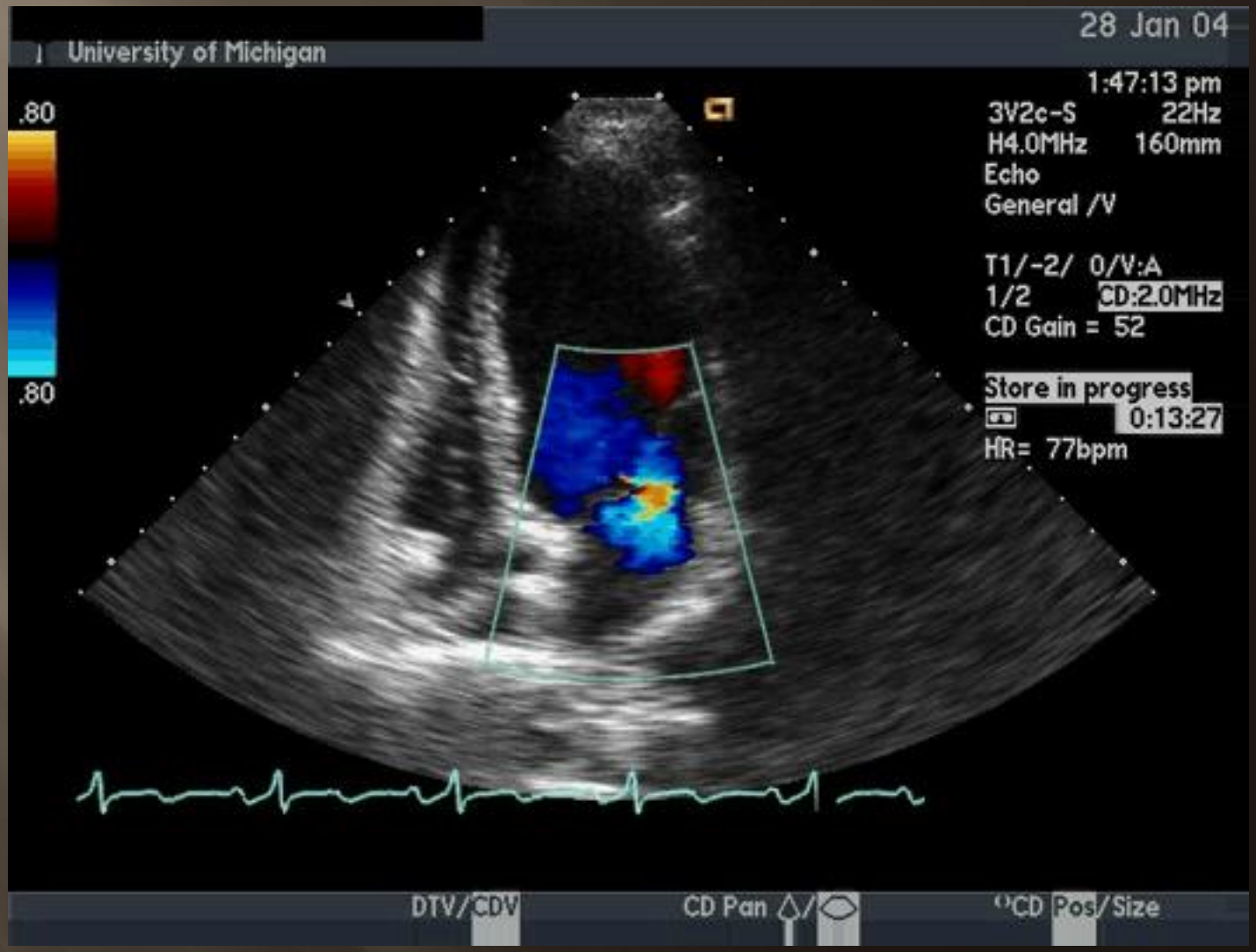
28 Jan 04
University of Michigan
1:47:13 pm
3V2c-S 22Hz
H4.0MHz 160mm
Echo
General /V
T1/-2/ 0/V:A
1/2 CD:2.0MHz
CD Gain = 52
Store in progress
0:13:27
HR= 77bpm
.80
.80
DTV/CDV
CD Pan
CD Pos/Size

NCBI Resources How To Sign in to NCBI

PubMed.gov
US National Library of Medicine
National Institutes of Health

PubMed | echocardiography, myocardial infarction | Search

RSS Save search Advanced Help

Show additional filters

**Article types**
Clinical Trial
Review
More ...

**Text availability**
Abstract
Free full text
Full text

**PubMed Commons**
Reader comments

**Publication dates**
5 years
10 years
Custom range...

Display Settings: Summary, 20 per page, Sorted by Recently Added

Send to:

**Results: 1 to 20 of 12815**

<< First < Prev Page 1 of 641 Next > Last >>

1. Inhibition of poly (ADP-ribose) polymerase and inducible nitric oxide synthase protects against ischemic **myocardial** damage by reduction of apoptosis.
   Wang J, Hao L, Wang Y, Qin W, Wang X, Zhao T, Liu Y, Sheng L, Du Y, Zhang M, Lu Q.
   Mol Med Rep. 2014 Nov 19. doi: 10.3892/mmr.2014.2977. [Epub ahead of print]
   PMID: 25412407 [PubMed - as supplied by publisher]

2. Echocardiographic assessment of global longitudinal right ventricular function in patients with an acute inferior ST elevation **myocardial infarction** and proximal right coronary artery occlusion.
   Hutyra M, Skála T, Horák D, Köcher M, Tüdös Z, Zapletalová J, Přeček J, Louis A, Smékal A, Táborský M.
   Int J Cardiovasc Imaging. 2014 Nov 18. [Epub ahead of print]
   PMID: 25404083 [PubMed - as supplied by publisher]
   Related citations

Filters: Manage Filters

**New feature**
Try the new Display Settings option - **Sort by Relevance**

**Results by year**

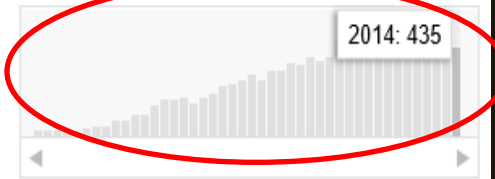


Download CSV

**PMC Images search for**
*echocardiography, myocardial infarction*

NCBI Resources How To Sign in to NCBI

PubMed.gov
US National Library of Medicine
National Institutes of Health

PubMed | echocardiography, myocardial infarction | Search

RSS Save search Advanced Help

Show additional filters

**Article types**
Clinical Trial
Review
More ...

**Text availability**
Abstract
Free full text
Full text

**PubMed Commons**
Reader comments

**Publication dates**
5 years
10 years
Custom range...

**Species**
Humans
Other Animals

Clear all

Display Settings: Summary, 20 per page, Sorted by Recently Added

Send to:

Filters: Manage Filters

**Results: 1 to 20 of 12815**

<< First < Prev Page 1 of 641 Next > Last >>

1. Inhibition of poly (ADP-ribose) polymerase and inducible nitric oxide synthase protects against ischemic **myocardial** damage by reduction of apoptosis.
Wang J, Hao L, Wang Y, Qin W, Wang X, Zhao T, Liu Y, Sheng L, Du Y, Zhang M, Lu Q.
Mol Med Rep. 2014 Nov 19. doi: 10.3892/mmr.2014.2977. [Epub ahead of print]
PMID: 25412407 [PubMed - as supplied by publisher]

2. Echocardiographic assessment of global longitudinal right ventricular function in patients with an acute inferior ST elevation **myocardial infarction** and proximal right coronary artery occlusion.
Hutyra M, Skála T, Horák D, Köcher M, Tüdös Z, Zapletalová J, Přeček J, Louis A, Smékal A, Táborský M.
Int J Cardiovasc Imaging. 2014 Nov 18. [Epub ahead of print]
PMID: 25404083 [PubMed - as supplied by publisher]
Related citations

3. Experimental heart failure causes depression-like behavior together with differential regulation of inflammatory and structural genes in the brain.
Frey A, Popp S, Post A, Langer S, Lehmann M, Hofmann U, Sirén AL, Hommers L, Schmitt A, Strekalova T, Ertl G, Lesch KP, Frantz S.
Front Behav Neurosci. 2014 Oct 31;8:376. doi: 10.3389/fnbeh.2014.00376. eCollection 2014.
PMID: 25400562 [PubMed] Free PMC Article

**New feature**
Try the new Display Settings option - **Sort by Relevance**

**Results by year**

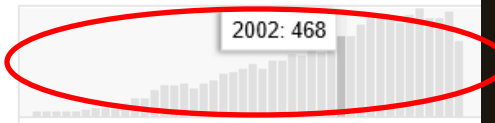


Download CSV

**PMC Images search for** *echocardiography, myocardial infarction*



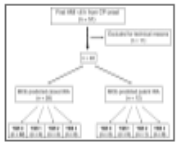

Int J Cardiovasc Imaging. 2014 Nov 18. [Epub ahead of print]

# Echocardiographic assessment of global longitudinal right ventricular function in patients with an acute inferior ST elevation myocardial infarction and proximal right coronary artery occlusion.

Hutyra M[1], Skála T, Horák D, Köcher M, Tüdös Z, Zapletalová J, Přeček J, Louis A, Smékal A, Táborský M.

Author information

## Abstract

Right ventricular (RV) myocardial infarction (MI) is a frequent concomitant of an acute inferior MI. We set out to determine the diagnostic value of speckle tracking echocardiography in comparison with cardiac magnetic resonance (CMR) for RV stunning and scar prediction. 55 patients (66 ± 11 years) with an acute inferior ST elevation MI who underwent percutaneous coronary intervention (PCI) of an occlusion in the proximal right coronary artery were prospectively enrolled. An echocardiography was done on the day of presentation and on the 5th day thereafter. A CMR was subsequently performed 1 month after the MI. The CMR was used to differentiate between the group with RV scar (n = 26) and without RV scar (n = 29). RV peak systolic longitudinal strain (RV-LS) at presentation determined RV scar (-21.1 ± 5.1 % vs. -9.9 ± 4.6 %, $p < 0.0001$). The RV-LS correlated with the scar extent ($r = 0.83$, $p < 0.0001$). RV-LS > -15.8 % had a sensitivity of 92 % and a specificity of 83 % in RV scar prediction (AUC 0.93). RV-LS was superior to TAPSE and TDI in determining the presence of RV scar. According to RV-LS values at presentation and on the 5th day, 3 subgroups were defined: G1-normal deformation (RV-LS <-20 %), G2-RV stunning (baseline RV-LS >-20 %, 5th day RV-LS <-20 %) and G3-persistent RV dysfunction (unchanged RV-LS > -20 %). In G1, there was neither RV scar nor clinically relevant hypotension. In G2, 58 % of patients developed RV scar and 36 % had hypotension. In the G3, 83 % developed RV scar and 55 % had hypotension. The myocardial deformation analysis could provide an early prediction of RV scar. It allowed the patients to be divided into subgroups with normal RV function, stunning and persistent RV dysfunction.

# Gelekcekte AKS ve EKO

- Kontrast ajanlar
- Teknik ilerlemeler
- Özel software
- Özel problar (intravasculer problar,….)

**References**


1. Peels CH, Visser CA, Kupper AJ, Visser FC, Roos JP. Usefulness of two-dimensional echocardiography for immediate detection of myocardial ischemia in the emergency room. *Am J Cardiol*. 1990 March 15;65(11):687–691.
2. Sabia P, Afrookteh A, Touchstone DA, Keller MW, Esquivel L, Kaul S. Value of regional wall motion abnormality in the emergency room diagnosis of acute myocardial infarction. A prospective study using two-dimensional echocardiography. *Circulation*. 1991 September;84(3 Suppl):I85–I92.
3. Colon PJ, 3rd, Guarisco JS, Murgo J, Cheirif J. Utility of stress echocardiography in the triage of patients with atypical chest pain from the emergency department. *Am J Cardiol*. 1998 November 15;82(10):1282–1284, A1210.
4. Gramiak R, Shah PM. Echocardiography of the aortic root. *Invest Radiol*. 1968 September–October;3(5):356–366.
5. Meza M, Greener Y, Hunt R, et al. Myocardial contrast echocardiography: reliable, safe, and efficacious myocardial perfusion assessment after intravenous injections of a new echocardiographic contrast agent. *Am Heart J*. 1996 October;132(4):871–881.
6. Shimoni S, Frangogiannis NG, Aggeli CJ, et al. Identification of hibernating myocardium with quantitative intravenous myocardial contrast echocardiography: comparison with dobutamine echocardiography and thallium-201 scintigraphy. *Circulation*. 2003 February 4;107(4):538–544.
7. Sabia PJ, Powers ER, Jayaweera AR, Ragosta M, Kaul S. Functional significance of collateral blood flow in patients with recent acute myocardial infarction. A study using myocardial contrast echocardiography. *Circulation*. 1992 June;85(6):2080–2089.

# SORULAR

- EKO kullanılıcak durumlar neler?
- EKO pencerelerinin yerleri ve en iyi görüntü pozisyonu nedir?
- Hangi pencereden hangi duvarı görürüm?
- Hangi koroner hangi duvarı besler?
- Hemodinamik bozukluğu olan AKS'lu hastada nelere dikkat etmeli?
- …….

# EVE GİDECEK MESAJ

- Normal EKG ve Biomarker varsa EKO
- RWMA AMI yada İskemi düşündürür
- Komplikasyonlar prognozu belirler bu yüzden önemlidir

# TEŞEKKÜRLER