İntraosseöz Girişim

Doç. Dr. Neslihan Yücel
İnönü Üniversitesi
Tıp Fakültesi
Acil Tıp Anabilim Dalı

Giriş

- Dolaşım için erişim sağlanması ressüsitasyonun en kritik bileşeni
- Resüsitasyon sırasında tercih edilen yol resüssitasyonun kesilmesini gerektirmeyen en büyük ve erişilebilir damar
- İlk tercih periferik venöz yol
- Yeniden canlandırma sırasında ve şok tedavisinde
  - çevresel venöz bir damar yolu kolaylıkla açılamaz ise (90 sn içerisinde) zaman kaybetmeden intraosseöz yol
- İlaçlar, kristalloidler, kolloidler, kan ve kan ürünleri hızlı ve güvenli verilebilir

İlk 1922'de tanımlandı

THE CIRCULATION IN THE MAMMALIAN BONE-MARROW[1]

WITH ESPECIAL REFERENCE TO THE FACTORS CONCERNED IN THE MOVEMENT OF RED BLOOD-CELLS FROM THE BONE-MARROW INTO THE CIRCULATING BLOOD AS DISCLOSED BY PERFUSION OF THE TIBIA OF THE DOG AND BY INJECTIONS OF THE BONE-MARROW IN THE RABBIT AND CAT

CECIL K. DRINKER, KATHERINE R. DRINKER AND CHARLES C. LUND

From the Laboratories of Physiology of the Harvard Medical School, Boston

Received for publication June 13, 1922

1940'larda yaygın olarak çocuklarda

Josefson, **A**. A new method of treatment - intraossal injections. Acta Med Scand **1934**; 81: 550-564.

Rapid Absorption of Substances Injected into the Bone Marrow

L. M. Tocantins

First Published October 1, 1940 | Research Article

Volume: 45 issue: 1, page(s): 292-296
Issue published: October 1, 1940
https://doi.org/10.3181/00379727-45-11657

Experimental Biology and Medicine

1940'larda yaygın olarak çocuklarda

PULMONARY FAT EMBOLISM FOLLOWING INFUSIONS VIA THE BONE MARROW[1]

UDO J. WILE, M.D., AND IRA LEO SCHAMBERG, M.D.

(Received for publication April 4, 1942)

October 11, 1941

INFUSIONS OF BLOOD AND OTHER FLUIDS VIA THE BONE MARROW

APPLICATION IN PEDIATRICS

L. M. TOCANTINS, M.D.; J. F. O'NEILL, M.D.; H. W. JONES, M.D.

JAMA. 1941;117(15):1229-1234. doi:10.1001/jama.1941.02820410007002

1940'larda yaygın olarak çocuklarda

October 1944

THE BONE MARROW AS AN ALTERNATE ROUTE FOR TRANSFUSION IN PEDIATRICS

HENRY A. REISMAN, M.D.; IRVING A. TAINSKY, M.D.

Am J Dis Child. 1944;68(4):253-256. doi:10.1001/archpedi.1944.02020100025006

December 12, 1942

MASSIVE INTRAMEDULLARY INFUSIONS

Ernest A. Doud, M.D.; John E. Tysell, M.D.

JAMA. 1942;120(15):1212-1213. doi:10.1001/jama.1942.82830500006010c

1940'larda yaygın olarak çocuklarda

INTRAOSSEOUS INFUSIONS IN INFANTS*

J. T. ELSTON, M.D.,† R. V. JAYNES, M.D.,† D. H. KAUMP, M.D., AND W. A. IRWIN, M.D.

From the Departments of Pediatrics,† Pathology and Radiology, Providence Hospital, Detroit, Michigan

October 11, 1946.

Ann Surg. 1945 Aug;122(2):266-77.

Complications of Intra-Osseous Therapy.

Tocantins LM, O'neill JF.

PMID: 17858653 PMCID: PMC1618242

1950 ve 1960’lar

Tek kullanımlık intravenöz kateterlerin geliştirilmesiyle birlikte popülerliğini kaybetmiştir

1980’lerde

Çocuklarda yapılan klinik çalışmalarda ve hayvan modellerinde etkili kullanımı ile ilgili sayısız makalelerden sonra intraosseöz uygulaması tekrardan yaygınlaşmıştır

1980'ler

Am J Emerg Med. 1988 Nov;6(6):577-9.

Intravascular access in pediatric cardiac arrest.

Brunette DD[1], Fischer R.

May 1985

Emergency Bone Marrow Infusions-Reply

ROBERT A. BERG, MD

Am J Dis Child. 1985;139(5):439. doi:10.1001/archpedi.1985.02140070012004

1980'ler

September 1984

Emergency Infusion of Catecholamines Into Bone Marrow

Robert A. Berg, MD

Am J Dis Child. 1984;138(9):810-811. doi:10.1001/archpedi.1984.02140470010003

N Engl J Med. 1990 May 31;322(22):1579-81.

Intraosseous infusion.

Fiser DH[1].

1980'ler

Ann Emerg Med. 1988 May;17(5):491-5.

Intraosseous infusions by prehospital personnel in critically ill pediatric patients.

Smith RJ[1], Keseg DP, Manley LK, Standeford T.

Ann Emerg Med. 1985 Dec;14(12):1135-40.

Comparison of intraosseous, central, and peripheral routes of sodium bicarbonate administration during CPR in pigs.

Spivey WH, Lathers CM, Malone DR, Unger HD, Bhat S, McNamara RN, Schoffstall J, Turner N.

1980'lerde

Intraosseous Infusion: An Alternative Route of Pediatric Intravascular Access

Substantial difficulties can be encountered when establishing rapid intravascular access in critically ill children. The historic technique of tibial intraosseous infusion is presented as an alternate intravenous route in children less than 3 years old. Review of the literature reveals this technique to be a rapid, reliable method with an acceptably low complication rate. Substances absorbed through the marrow, flow rates, technical difficulties, and complications are discussed. [Rosetti VA, Thompson BM, Miller J, Mateer JR, Aprahamian C: Intraosseous infusion: An alternative route of pediatric intravascular access. Ann Emerg Med September 1985;14:885-888.]

Valerie A Rosetti, MD
Bruce M Thompson, MD
Jeff Miller, MD
James R Mateer, MD
Charles Aprahamian, MD
Milwaukee, Wisconsin

From the Section of Trauma and Emergency Medicine, Medical College of Wisconsin, Milwaukee, Wisconsin.

Received for publication September 6, 1984. Revision received January 28, 1985. Accepted for publication March 25, 1985.

INTRODUCTION

Obtaining emergency intravascular access in critically ill pediatric patients, especially those less than 3 years old, can be extremely difficult, time consuming, and at times impossible. Peripheral veins often are collapsed,

Kılavuzlara girişi

American Heart Association and American Academy of Pediatrics: Textbook of pediatric advanced life support. American Heart Association 1988; 43-44.

European Resuscitation Council

Paediatric advanced life support

To be read in conjunction with the International Liaison Committee on Resuscitation Paediatric Working Group Advisory Statement (April 1997)

Kılavuzlara girişi

European Resuscitation Council Guidelines for Resuscitation 2005
Section 4. Adult advanced life support

Jerry P. Nolan, Charles D. Deakin, Jasmeet Soar,
Bernd W. Böttiger, Gary Smith

2005 AMERICAN HEART ASSOCIATION GUIDELINES FOR CARDIOPULMONARY RESUSCITATION AND EMERGENCY CARDIOVASCULAR CARE

Part 7.2: Management of Cardiac Arrest

Cihazlar

- Manual IO iğneler
  - İnfantlarda
- Pil ile çalışan drill (EZIO)
  - 1 yaş üzeri çocuklar, adölasan ve erişkin
- Kemik enjeksiyon tabancası
  - FAST 1 (sternum)

Made with
VideoShow

Venöz drenaj

© 2018 UpToDate, Inc. and/or its affiliates. All Rights Reserved.

Venous drainage from marrow of long bone with intramedullary needle in place

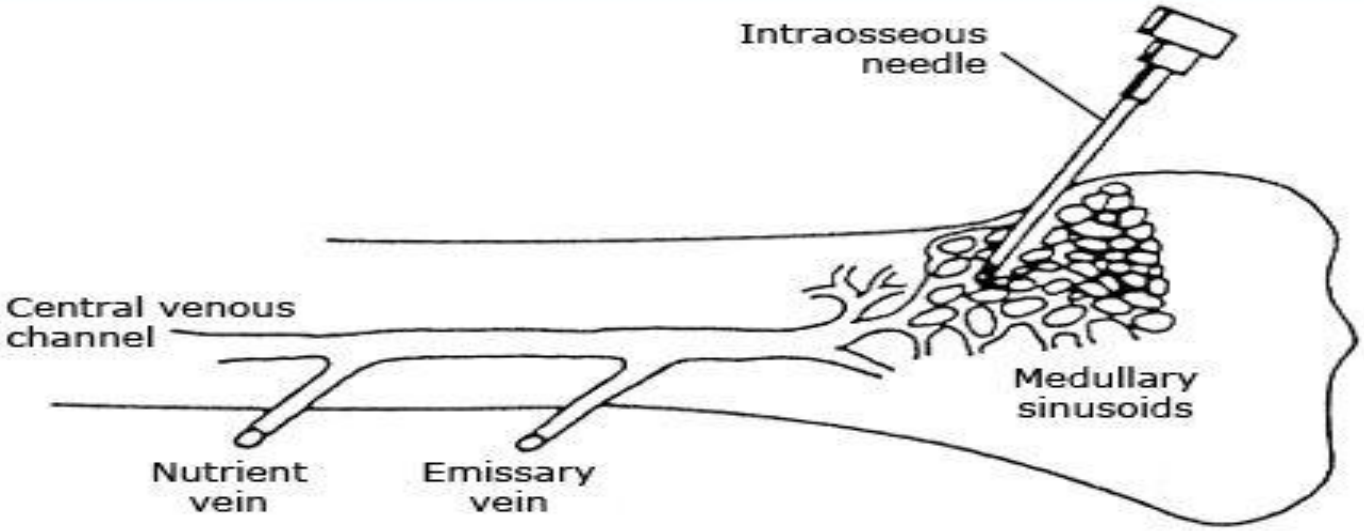

The veins that drain the medullary sinuses of the long bones are supported by the bony matrix. They do not collapse in shock or hypovolemia.

Uygulanabileceği kemikler

- Proksimal tibia – Popliteal ven
- Distal tibia (medial malleolus) – büyük safen ven
- Distal Femur – Femoral ven dalları
- Proksimal humerus – aksiller ven
- Manubrium sterni – internal mamary ya da azigos ven
  - Ayrıca klavikula, distal radius, radiyal sitiloid ve kalkaneusta başarıyla kullanılmıştır

Uygulama alanları

© 2018 UpToDate, Inc. and/or its affiliates. All Rights Reserved.

Proximal tibial intraosseous access site

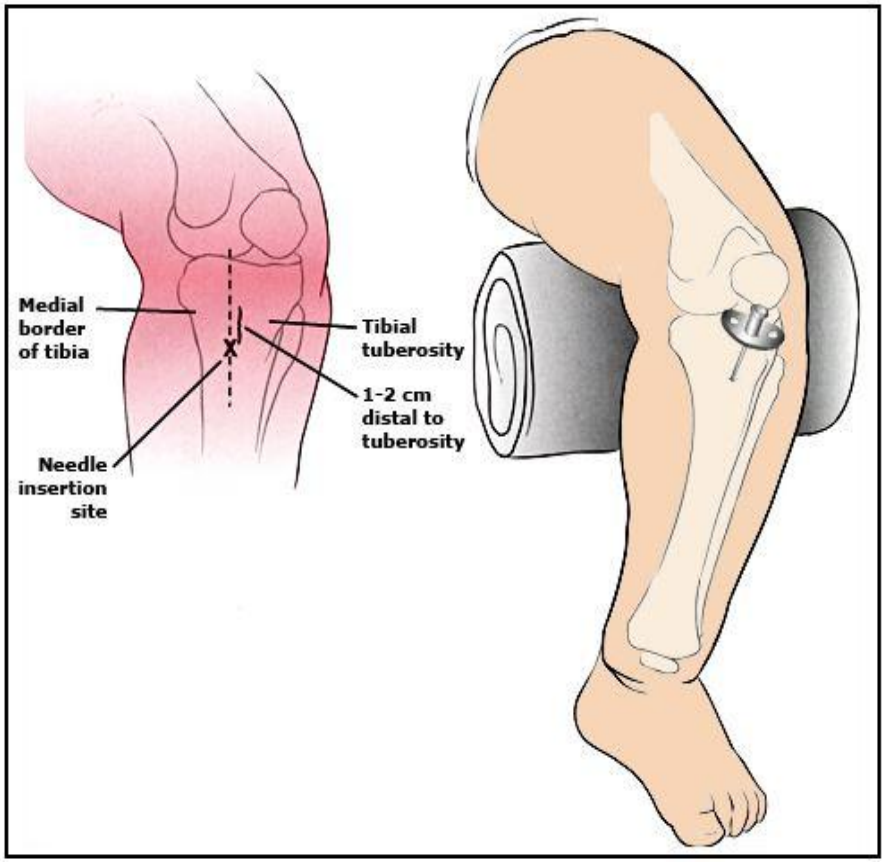

Distal tibial intraosseous access site

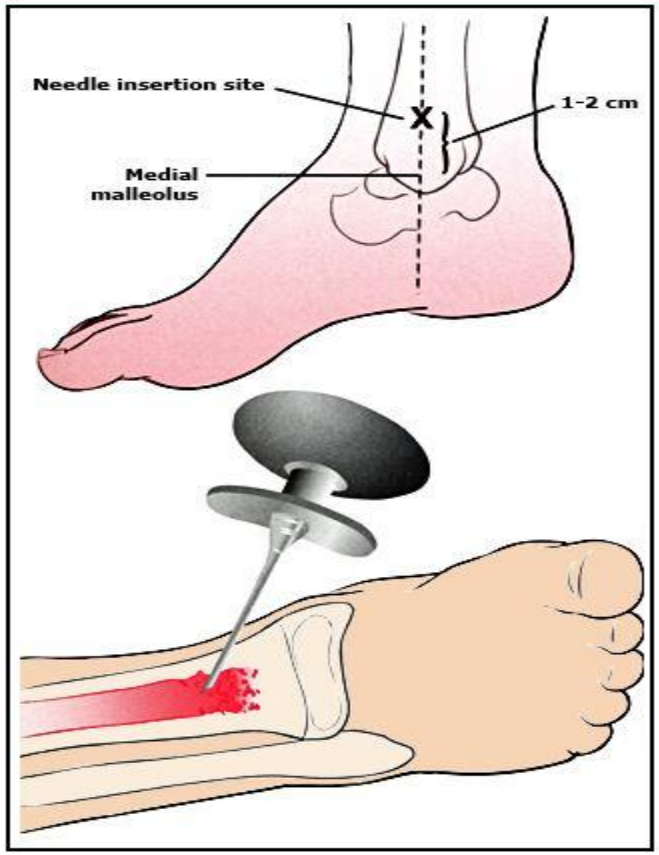

Uygulama alanları (2018 up todate)

Femoral intraosseous access site

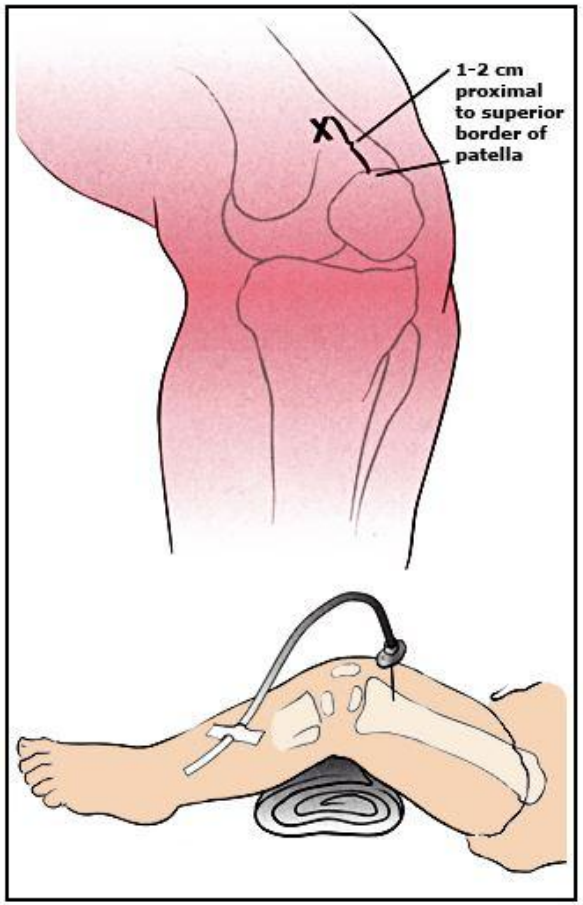

Proximal humeral intraosseous access site

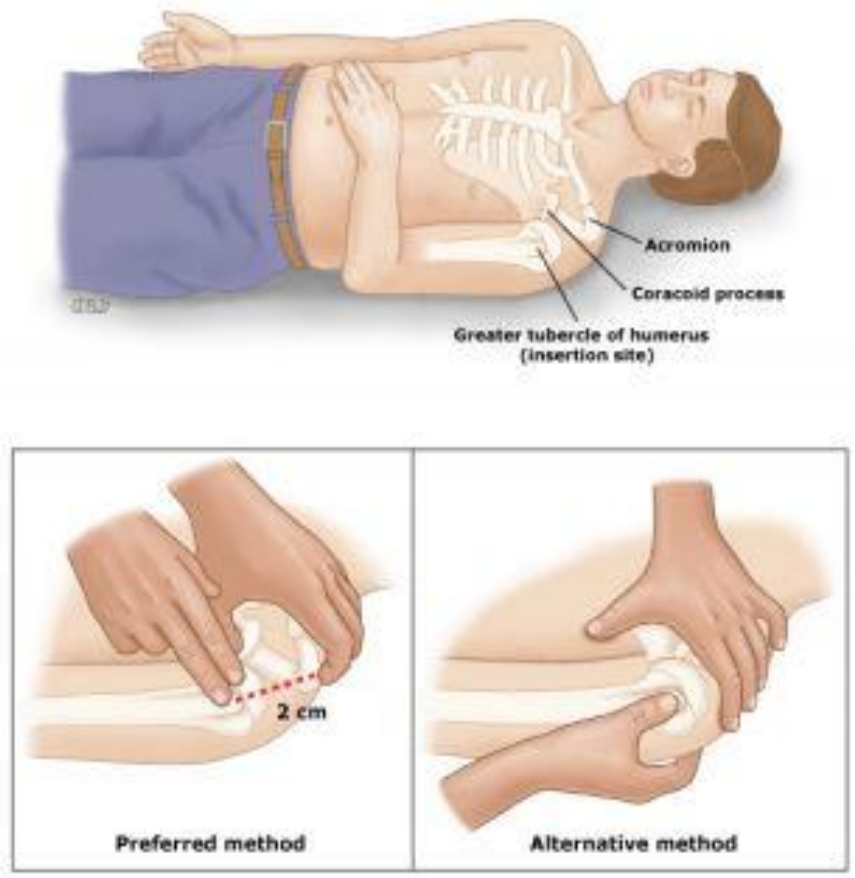

Yaşlara göre uygulanabilecek kemikler

Hasta yaşı	İntraosseöz uygulanabilecek bölge
İnfant (1 yaş altı)	Proksimal tibia Distal femur
Çocuk (1-12 yaş)	Proksimal tibia Distal tibia ya da fibula
12-18 yaş	Proksimal tibia Distal tibia ya da fibula Sternum
18 yaş üzeri	Proksimal tibia Proksimal humerus Distal tibia ya da fibula Sternum

Endikasyonları

- Kardiyopulmoner arrest ya da ciddi şoktaki erişkin, çocuk ve infant
- Acil müdahele gereken durumlar
  - geniş yanık, şok, sepsis, hipotermi
  - status epileptikus, travma, KOAH,
  - Vanöz yol sağlamada güçlük (fistül, greft, shunt, mastektomi veya çoklu kateter yerleşimi, morbid obezite)
  - tıbbi olarak damar yolu açılması gereken ancak damar yolu açılamayan hastalarda (ilaç infüzyonu vb)

Kontrendikasyonları

- Kesin
  - Kırık ya da daha önceden intraosseöz girişim denenmiş ise
  - Travma/cutdown nedeniyle vasküler yaralanma
  - Enfeksiyon (selülit, yanık ya da osteomyelit)
  - Geçirilmiş sternotomi
- Rölatif
  - Osteoporoz ya da osteogenez imperfekta ve sağdan sola şant (Fallot tetralojisi, pulmoner atrezi)
  - Protez (diz protezi, çivi, plak)
  - Anatomik yapıyı belirlemede zorluk

Komplikasyonları

- **İntraosseöz girişimin komplikasyon oranı <%1**
- Potansiyel komplikasyonları
  - Yanlış yerleştirmeye bağlı ektravazasyon
  - Kırık
  - Kompartman sendromu,
  - Deri nekrozu,
  - Osteomyelit (hasar görmüş, enfekte ya da yanık olan bölgeden girişimin yapılması ve cihaz 24 sa uzun kalırsa
  - subkutan abse
  - Pnömotoraks, damar yaralanması, mediastinit (sternum)

Komplikasyonları

- Uzun dönemde gelişebilecek komplikasyonu ise
  - Kemik iliğinde hasar,
  - Kemik gelişiminde bozulma (epifiz hasarına bağlı)
  - Yağ ya da kemik iliği embolisidir

İlaçlar ve dozları

- İntravenöz yol ile kullanılan tüm ilaçlar güvenle aynı dozda intraosseöz yoldan verilebilir, her ilaçtan sonra flush yapılmalıdır
  - Epinefrin, atropin, lidokain, amiadaron, sodyum bikarbonat
  - dopamin, dobutamin,
  - digital, heparin,
  - fenitoin, noromüsküler bloke eden ajanlar,
  - antibiyotikler, anestezik ajanlar
  - Kristaloidler, kolloidler ve kan ürünleri vs
  - Adenozin verilebilir, iv ile verildiği kadar etkili değil

İlaç ve sıvı tedavisi dışında

- Tanısal çalışmalar
- Venöz kan alınabilir ve bu kanda
  - Glukoz, hemoglobin, pH, $PaCO_2$, serum bikarbonat, Na, Cl, kan üre azotu, kreatinin, serum ilaç seviyeleri ve kültürler
  - Ancak PaO_2, BK, K, AST, ALT, trombosit veya iyonize Ca için kemik iliği değerleri doğru olmayabilir
  - Kemik iliği aspirasyonu ile ABO ve Rh tiplemesi doğru olarak yapılır
  - İlaç uygulamasından sonra örnek alınmamalıdır

İntraosseöz

- Geçici hızlı vasküler yol sağlar
- Mümkün olan en kısa sürede venöz yol açılıp intraosseöz iğne çıkarılmalıdır

Günümüzde

Resuscitation. 2018 Apr 5. pii: S0300-9572(18)30162-X. doi: 10.1016/j.resuscitation.2018.04.003. [Epub ahead of print]

Anatomical investigations on intraosseous access in stillborns - comparison of different devices and techniques.

Fuchs Z[1], Scaal M[2], Haverkamp H[3], Koerber F[4], Persigehl T[4], Eifinger F[5].

RESULTS: Estimated success rate was 61.1% (95%CI:39.7%-78.9%) for the Butterfly needle, 43.0% (95%CI:23.4%-65.0%) for hand-twisted EZ-IO® screwing and 39.7% (95%CI:24.1-57.7%) for the semi-automatic drill (Arrow®EZ-IO®), all referring to an average diameter of the corticalis of 1.2 mm. The odds of a correct position were 2.4 times higher (95%CI:0.8-7.6) when using the Butterfly needle than with the drill. In contrast, the odds of correct positioning when inserting the needle by hand were not significantly different from using the drill (odds ratio 1.1, 95%CI: 0.4-3.3). Neither of these effects nor the diameter of the corticalis with an odds ratio near one were significant in the model. Median diameter of the bone marrow cavity was 4.0 mm [IQR 3.3-4.7].

CONCLUSION: Intraosseous access for premature and neonatal infants could be best achieved by using a manually twisted Butterfly needle.

Günümüzde

J Trop Pediatr. 2018 Apr 1;64(2):132-140. doi: 10.1093/tropej/fmx061.

Intraosseous Versus Intravenous Access in Pediatric Septic Shock Patients Admitted to Alexandria University Pediatric Intensive Care Unit.

El-Nawawy AA[1], Omar OM[1], Khalil M[1].

Author information

Abstract

The cornerstone of emergency management of sepsis is early, goal-directed therapy. The purpose of this study was to evaluate the effect of intraosseous (IO) vs. intravenous (IV) access for resuscitation of patients with septic shock admitted to pediatric intensive care unit. This prospective interventional randomized clinical trial study was conducted on 60 patients with septic shock who need rapid administration of fluids and drugs; 30 cases were randomly chosen for IO vascular access, while the other 30 were selected for IV access. The IO route was successfully secured in all cases with a significant shorter time of vascular access insertion, shorter length of stay and reduction in mortality in IO group vs. IV group ($p = 0.001$, 0.045, 0.002, respectively). In pediatric emergencies, as in case of shock, the use of IO route is recommended to get rapid vascular access as soon as possible, as it revealed better outcome.

Günümüzde

J Trauma Acute Care Surg. 2018 Feb 17. doi: 10.1097/TA.0000000000001850. [Epub ahead of print]

Emergency sternal intraosseous access for warm fresh whole blood transfusion in Damage Control Resuscitation: 'Sternal intraosseous access in DCR'.

Bjerkvig CK[1], Fosse T, Apelseth TO, Sivertsen J, Braathen H, Eliassen HS, Guttormsen AB, Cap AP, Strandenes G.

⊕ **Author information**

RESULTS: Median reinfusion time was 46.2 ml/min in the FAST1 group, 32.4 ml/min in the T.A.L.O.N. group and 74.1 ml/min in the IV group. Blood samples from all participants were within normal ranges. There was no statistically significant difference in haptoglobin and lactate dehydrogenase between the groups. In the Fast 1 group 1/11 (9%) procedures failed. In the T.A.L.O.N group 4/14 (29%) procedures failed.

CONCLUSION: Although preferable, achieving peripheral venous access in the bleeding patient is a major problem. Our findings suggest that fresh whole blood transfusion through the IO route is safe, reliable and provide sufficient flow for resuscitation.

LEVEL OF EVIDENCE: Level III Therapeutic/Care management.

Günümüzde

Pediatr Crit Care Med. 2018 Feb 9. doi: 10.1097/PCC.0000000000001508. [Epub ahead of print]

Duration to Establish an Emergency Vascular Access and How to Accelerate It: A Simulation-Based Study Performed in Real-Life Neonatal Resuscitation Rooms.

Schwindt EM[1], Hoffmann F[2], Deindl P[3], Waldhoer TJ[4], Schwindt JC[5].

MEASUREMENTS AND MAIN RESULTS: The duration of access establishment (time from decision to first flush/aspiration), preparation (decision to start of procedure), and the procedure itself (start to first flush/aspiration) was significantly longer for umbilical venous catheter than for intraosseous access (overall duration 199 vs 86 s). Delaying factors for umbilical venous catheter establishment were mainly due to the complex approach itself, the multitude of equipment required, and uncertainties about necessary hygiene standards. Challenges in intraosseous access establishment were handling of the unfamiliar material and absence of an intraosseous access kit in the resuscitation room. There was no significant difference between the required duration for access establishment between large centers and small hospitals, but a trend was observed that duration for umbilical venous catheter was longer in small hospitals than in centers. Duration for intraosseous access was similar in both hospital types.

CONCLUSIONS: Vascular access establishment in neonatal resuscitation could be accelerated by infrastructural improvements and specific training of medical teams. In simulated in situ neonatal resuscitation, intraosseous access is faster to establish than umbilical venous catheter. Future studies are required to assess efficacy and safety of both approaches in real resuscitation settings.

Günümüzde

Mil Med. 2018 Feb 6. doi: 10.1093/milmed/usx078. [Epub ahead of print]

Military Medic Performance with Employment of a Commercial Intraosseous Infusion Device: A Randomized, Crossover Study.

Gendron B[1], Cronin A[1], Monti J[1], Brigg A[2].

CONCLUSIONS: The overall first-attempt success rates of U.S. Army Combat Medics employing the EZ-IO® System are similar to the success rates of FAST1® device employment and similar to the success of other provider cohorts using the EZ-IO® device. Coupled with perceived benefit of adding the EZ-IO® System to their combat medic skillset, these data warrant further study and consideration for the incorporation of commercial IO systems into U.S. Army Combat Medic initial, sustainment, and pre-combat training and standard issue equipment.

Günümüzde

Pediatr Crit Care Med. 2018 Apr;19(4):332-338. doi: 10.1097/PCC.0000000000001493.

Review of Routes to Administer Medication During Prolonged Neonatal Resuscitation.

Wagner M[1,2], Olischar M[1], O'Reilly M[2,3], Goeral K[1], Berger A[1], Cheung PY[2,3], Schmölzer GM[2,3].

CONCLUSIONS: Based on animal studies, endotracheal tube administration of medications requires a higher dose than that by peripheral intravascular access or umbilical venous catheter. Epinephrine via laryngeal mask airway is feasible as a noninvasive alternative approach for drug delivery. Intraosseous access should be considered in situations with difficulty in establishing other access. Randomized controlled clinical trials in neonates are required to compare all access possibilities described above.

Günümüzde

Ann Emerg Med. 2018 Jan 6. pii: S0196-0644(17)31907-8. doi: 10.1016/j.annemergmed.2017.11.015. [Epub ahead of print]

Intraosseous Vascular Access Is Associated With Lower Survival and Neurologic Recovery Among Patients With Out-of-Hospital Cardiac Arrest.

Kawano T[1], Grunau B[2], Scheuermeyer FX[3], Gibo K[4], Fordyce CB[5], Lin S[6], Stenstrom R[2], Schlamp R[7], Jenneson S[8], Christenson J[8].

RESULTS: Of 13,155 included out-of-hospital cardiac arrests, 660 (5.0%) received intraosseous vascular access. In the intraosseous group, 10 of 660 patients (1.5%) had favorable neurologic outcome compared with 945 of 12,495 (7.6%) in the intravenous group. On multivariable regression, intraosseous access was associated with poorer out-of-hospital cardiac arrest survival (adjusted odds ratio 0.24; 95% confidence interval 0.12 to 0.46). Sensitivity analyses revealed similar results.

CONCLUSION: In adult out-of-hospital cardiac arrest patients, intraosseous vascular access was associated with poorer neurologic outcomes than intravenous access.

Günümüzde

J Trauma Acute Care Surg. 2018 Feb;84(2):379-385. doi: 10.1097/TA.0000000000001741.

No intravenous access, no problem: Intraosseous administration of tranexamic acid is as effective as intravenous in a porcine hemorrhage model.

Lallemand MS[1], Moe DM, McClellan JM, Loughren M, Marko S, Eckert MJ, Martin MJ.

RESULTS: After hemorrhage and ischemia-reperfusion, there were no significant differences in mean arterial pressure (48 vs. 49.5), lactate (11.1 vs. 10.8), and pH (7.20 vs. 7.22) between groups. Intraosseous TXA corrected the lysis index at 30 minutes in EX-TEM and IN-TEM, like IV infusion. Peak serum levels of TXA after IV and IO administration show concentrations of 160.9 µg/mL and 132.57 µg/mL respectively ($p = 0.053$). Peak levels occurred at the completion of infusion. Drug levels were tracked for four hours. At the end of monitoring, plasma concentrations of TXA were equivalent.

CONCLUSION: Intraosseous administration of TXA is as effective as IV in reversing hyperfibrinolysis in a porcine model of hemorrhagic shock. Intraosseous administration was associated with a similar peak levels, pharmacokinetics, and clearance. Intraosseous administration of TXA can be considered in hemorrhagic shock when IV access cannot be established.

- **Teşekkürler……**